

Management of Conductive hearing loss due to Adhesive Otitis media with Ayurveda: A Case report.

Rozina Khoja,^{1*} Abhishek Sager,¹ D.B. Vaghela²

¹MS (Ayu) Scholar, ² Associate Professor & I/C HOD, Department of Shalakya Tantra, IPGT & RA, Gujarat Ayurved University, Jamnagar, Gujarat, India.

Abstract:

Conductive hearing loss occurs when there is a problem in conducting sound waves anywhere along the route through the outer ear, Tympanic membrane or Middle ear. Children are more affected with conductive hearing loss. It affects 4% of all school going children. In present study we have discussed a case of a 16-year-old female child who came to OPD with complains of decreased hearing and common cold since three years. Audiometry report showed bilateral mild to moderate conductive hearing loss. First Ayurveda treatment of *Pratishyaya* with three sittings of *MarshaNasya* of *AnuTaila* were given after that her hearing improved showing audiometric findings of normal hearing in left ear and moderate conductive loss in right ear. We continued same treatment for next month. After Three months repeat Audiometry was done, which showed normal Hearing in left ear. Patient also felt better hearing in both ears. Conductive hearing loss due to adhesive tympanic membrane is result of Eustachian tube blockage, which can be easily managed with the help of Ayurveda treatment- *MarshaNasya* with *Pratishyaya* treatment. Hearing loss to school going children is a very serious problem affecting their education, skills and social relationship with others. With this study we can cure this type of deafness without any surgical intervention and help them to live their life in a better way.

Key words: Adhesive otitis media, *Badhirya*, Conductive deafness, Eustachian tube blockage, *Nasya*,

Received: 24.12.2018

Revised: 28.12.2018

Accepted: 30.12.2018



*CORRESPONDING AUTHOR:

Rozina Khoja^{1*}

MS Scholar, Shalakya Tantra Department, IPGT & RA, GAU, Jamnagar, Gujarat, India.

Email: rozinakhoja28@gmail.com

Mobile: +918866337312

Introduction:

Hearing loss is a partial or complete inability to receive and interpret sound stimuli in one or both ears. Hearing loss is categorized into Conductive, Sensorineural and Mixed hearing loss on the basis of pathogenesis. Childhood hearing loss can be a debilitating condition that affects a significant degree of physical, mental and social health. Conductive hearing loss is most common hearing loss in children which accounts for 85 to 90% of childhood hearing loss in India.^[1] Increasingly more attention is being focused on mild or slight hearing impairment > 20dB HL including unilateral or bilateral loss that may affect 10 to 15% of school-aged children with deleterious effects on school performance and social emotional development.^[2] Conductive hearing loss occurs when the outer or middle ear structures fail to optimally capture, collect, or transmit sound from the environment to the cochlea. Fluid accumulation is the most common cause of conductive hearing loss in middle ear, especially in children. Major causes are ear infections or conditions that block the Eustachian tube, such as Allergies or Tumors. Eustachian tube dysfunction can lead to excessive negative pressure against the ear drum, causing it to collapse and may require surgical intervention.^[3] Causes of Conductive hearing loss are Acute otitis media, Otitis media with effusion or “glue ear”, Perforated eardrum, Chronic suppurative otitis media, Cholesteatoma, Otosclerosis, Middle ear tumour, Ossicular discontinuity, Congenital malformation of ossicles, Barotrauma.^[4] Main Examinations for hearing loss are Otoscopy, Differential

testing, Tympanometry, Audiometry, CT Scan.^[5]

Eustachian tube dysfunction and resultant negative middle ear pressure result in tympanic membrane retraction and middle ear atelectasis. Retraction pockets are especially common in pars flaccid and posteriosuperior quadrant of the pars tensa. In these areas, retraction pocket can deep over the ossicles resulting in erosion and ossicular discontinuity. Insertion of a tympanostomy tube may be helpful in reversing this process. The atelactic tympanic membrane should be evaluated with pneumatic insufflations. Failure of the TM to separate from the promontory and ossicular chain may be due to significant negative middle ear pressure. However, it is also possible that the TM is bound to the underlining structure as a result of adhesive otitis media, a fibrous tissue proliferation that occasionally occurs in response to inflammation. Adhesive otitis media may result in a conductive loss owing to reduced compliance of the tympanic membrane or reduced mobility of the ossicular chain. However, Patient with adhesive otitis media often retains excellent hearing. A reasonable alternative is close monitoring and intervention only in case of accumulation of squamous debris or deterioration in hearing. In children, a rush to address this process at an age which Eustachian tube function is not well developed may result in recurrent middle ear atelectasis.^[6] Management falls into three modalities: Surgical treatment, Pharmaceutical treatment, and Supportive, depending on the nature and location of the specific cause. In case of infection,

antibiotics or antifungal medications are an option. Some conditions are amenable to surgical intervention such as middle ear fluid, cholesteatoma, otosclerosis. If conductive hearing loss is due to head trauma, surgical repair is an option.^[7] If absence or deformation of ear structure cannot be corrected, or if the patient declines surgery, hearing aids which amplify sound are a possible treatment option.^[8] Bone conduction hearing aids are useful as these deliver sound directly to the cochlea bypassing the pathology. These can be on a soft or hard headband or can be inserted surgically, a bone anchored hearing aid, of which there are several types. Conventional air conduction hearing aids can be used. Severe retraction of the ear drum may necessitate ear tube surgery or a surgery to rebuild the ear drum (Tympanoplasty).^[9]

Case Report:

A 16 years old female child came to OPD of Shalakyantra department with her parents with the complains of decreased hearing bilateral since 4 years and recurrent nasal blockage since 6 years. It was affecting on her social development like school education etc. she was having history of recurrent common cold during her child hood with complains of nasal blockage.

Then after she got developed complains of decreased hearing in both ears gradually since 4 years. Family History have No any family history was found. On Ear Examination byOtoscopy we ffound EAC: B/L Clear, TM: B/L Adhesive tympanic membrane, Rinne's test: Bilateral, Bone conduction>Air conduction, Weber's test: Lateralized to right ear. Audiometry shows Bilateral Mild to Moderate conductive hearing loss. (08/03/2018) On General ExaminationWeight-42 Kg, Height-154cm, Pulse rate-72/min, BP-110/82 mmHg. In Personal History patient was Vegetarian, Appetite Good, Bowel Regular, Micturation Normal, Sleep Normal We Diagnosed as *Badhira* (Disease ID-1896, Disease Code J-19)^[10] (Conductive Hearing loss due to Adhesive otitis media) On examination adhesive tympanic membrane seen and Rinne's test shows bilateral bone conduction greater than air conduction, Audiometry shows B/L conductive hearing loss so it can be diagnosed as conductive hearing loss due to adhesive otitis media.

The patient was given Ayurveda treatment with holistic approach i.e. *Shodhana* and *Shamana* treatment with *Pathyaapathya*. Treatment prescribed from was as following:(Table : 1)

Table:1

1	Combination of; <i>SitopaladiChurna</i> -2gm <i>VasaChurna</i> -1gm <i>BharangiChurna</i> -1gm <i>NaradiyaLaxmivilasaRasa</i> -125mg	TID Orally	With Honey	2 Months
---	--	---------------	------------	----------

	Total-4.125gm			
2.	<i>LavangadiVati</i> for Chewing	One Tab. QID	For Chewing	2 months
3.	<i>AnuTaila</i>	6-6 drops each nostril once daily in the morning	<i>MarshaNasya</i> as per classical method	Three sitting each of Seven days of interval

Table: 2: Pathyaapathya(Described for *PratishyayaRogi*)^[11]

PATHYA	APATHYA
<i>Ushnodakasevana</i>	<i>ShitaAmbu</i>
<i>Nirvatashyyaasana Sevana</i>	<i>ShishiraAvagaha</i>
<i>Murdhno Ushnavasah sevan</i>	<i>Chinta</i>
<i>Ruksha Yava Anna</i>	<i>Atiruksha Ashan</i>
	<i>VegaAvarodha</i>
	<i>Shoka</i>
	<i>Navina Madhya</i>

Result:

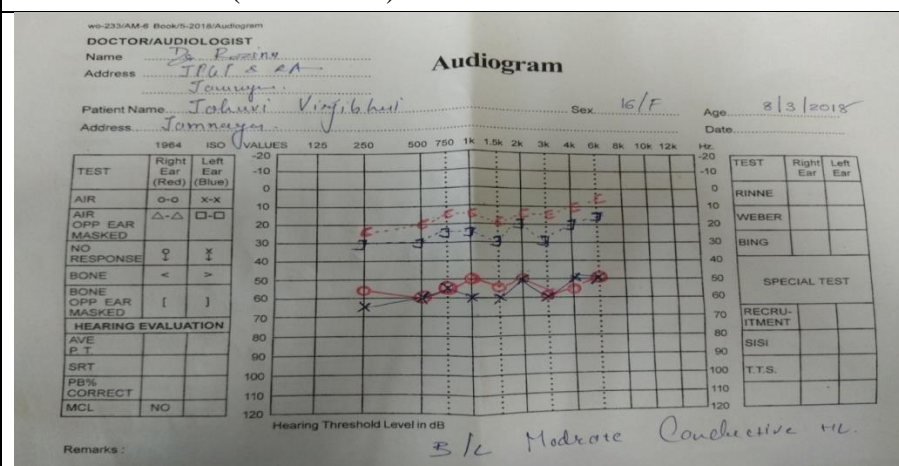
After 1 month of treatment repeat Audiometry was done (30/4/2018), which showed Normal hearing in right ear and moderate conductive hearing loss in left ear.

So, same treatment protocol was continued for next month. After completion of treatment we performed Audiometry (28/06/2018), which showed normal hearing in both ears. (Table: 3)

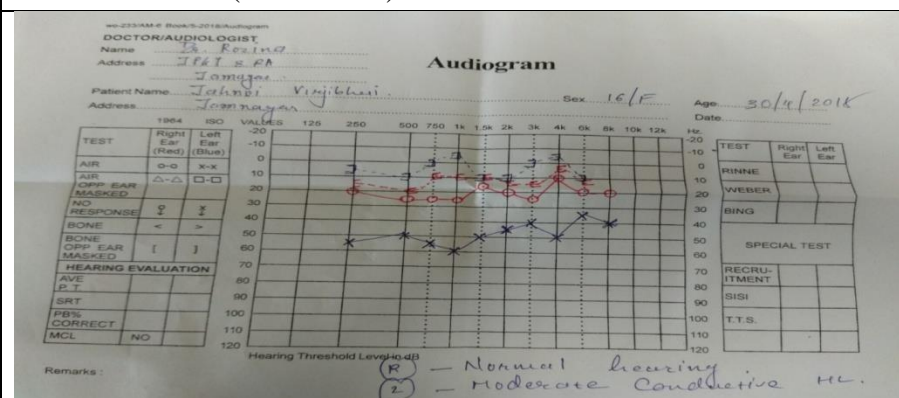
Table: 3

Date	08/03/2018	30/04/2018	28/06/2018
Audiometry Report	B/L Modrate Conductive hearing loss	Right: Normal hearing Left: modrate conductive Hearing loss	Right: Normal hearing Left: Normal hearing

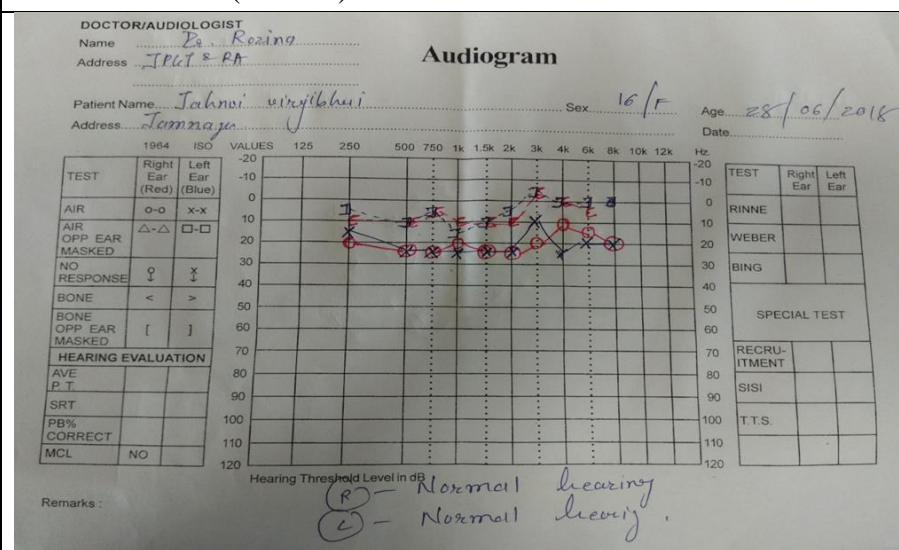
AUDIOMETRY(08/03/2018)



AUDIOMETRY(30/04/2018)



AUDIOMETRY(28/06/2)



Discussion:

Children with complain of recurrent common cold are prone to have conductive hearing loss due to blockage of Eustachian tube. Tubal blockage leads to decreased middle ear pressure because of that, tympanic membrane starts retracting and in chronic case it results in Adhesive otitis media. Due to this problem sound waves are not able to reach over cochlea and it results in conductive hearing loss. According to *Acharya Shushruta* in *Badhira Vata Dosha* is *Avaruta* by *Kapha Dosha* in *Shabdavaha Sira*.^[12] *Badhira* is also given as a first *Upadrava* of *Pratishyaya*.^[13] And for the treatment of *Badhira*, line of treatment described in *Pratishyaya* and *Vatvyadhi* is indicated by *Acharya Shushruta*.^[14] In Present case we selected treatment of *Pratishyaya* (*Shitopaladi Churna* with *Vasa, Bharangi* and *Naradiya Laxmivilasa Rasa*) with *Anupana* of *Madhu* and *Anutaila Marsha Nasya* to remove *Avarana* of *Kapha* over *Vata dosha* so *Sampraptivighatana* will happen and *Sanchaya* of *Dosha* from *Shabdavahasira* will be clear. *Shitopaladi Churna* with *Vasa Churna, Bharangi Churna*, and *Naradiya Laxmivilasa Rasa* will act as decongestants and reduce edema of Eustachian tube. *Lavangadi Vati* (*Lavanga, Maricha, Haritaki, Khadirasara, Babbula*)^[15] was used as lozenges which causes movement of pharyngeal muscles and opening of Eustachian tube, resulting in middle ear ventilation and increase middle ear pressure. *Nasya* with *Anutaila* will directly act on Nasopharyngeal opening of Eustachian tube and it will reduce its edema and obstruction so it can ventilate middle ear. During two

months of treatment period and follow up we have not encountered any ADE/R related to oral treatment or *Nasya* in the patient. Patient and her family were very happy that her hearing was improved to normal and they were suggested for surgery from allopathic medicine before 3 years. Patient was prescribed routine and classical Ayurveda medicine and was not treated with any intentions of future publication we have not taken any accent of patient or prior informed consent from patient.

Conclusion:

Conductive hearing loss due to Adhesive Otitis media is due to Eustachian tube blockage. Modern rehabilitation strategies are partly effective but under used. Ayurveda has a variety of medicines and procedures to treat deafness due to Eustachian tube dysfunction. This case study indicates effectiveness of Ayurveda in management of *Badhira* due to Adhesive otitis media.

References:

1. <http://www.indianjotol.org/>. [Last Accessed on 2018 dec.12]
2. Dodd-Murphy & Mamlin 2002; Lieu 2004; Wake & Poulakis 2004; Lieu et al. 2010 Lippincott Williams & Wilkins EAR AND HEARING 2017 jan; 38(1): 7-20.
3. <http://www.audicus.com/>. [Last Accessed on 27 June 2018 Time: 6:30pm]
4. <https://en.m.wikipedia.org/>. [Last Accessed on 28 June 2018 Time 7:45 pm]

5. Advance theory of Otitis media: Cuneyt M. Alper, Charles D. Blestar, print 2004 BC Decker /nc Hamilton.London. Chepter-85, P-420
6. “Types, Causes and Treatment” Hearing Loss Association of America. Retrived 8 june 2013
7. Ruben, Robert J. “Hearing Loss and Deafness” The Merck Manual. Retrieved 8 June 2013.
8. <https://www.entnet.org/>. [Last Accessed on 29/6/2018]
9. <http://namstp.ayush.gov.in/>. [Last Accessed on 2018 , 7 July, Time 5:25pm]
- 11 Shastri AD. Sushruta, Shushrut samhita, Chaukhamba Sanskrit Prakashana, Varanasi, reprint 2014, Uttartantra 24/21-22.
12. Shastri AD. Sushruta, Shushrut samhita, Chaukhamba Sanskrit Prakashana, Varanasi, reprint 2014, Uttartantra 20/08.
13. Shastri AD. Sushruta, Shushrut samhita, Chaukhamba Sanskrit Prakashana, Varanasi, reprint 2014, Uttartantra 24/16-17.
14. Shastri AD. Sushruta, Shushrut samhita, Chaukhamba Sanskrit Prakashana, Varanasi, reprint 2014, Uttartantra 21/38.
15. Vaidyajivana, Shwasa-Kasa Chikitsa, 7, AFI Vol 1 Page no.192.

Guarantor: Corresponding author is guarantor of this article and its contents.

Conflict of interest: Author declares that there is no conflict of interest.

How to cite this article:

Khoja R, Sager A, Vaghela DB. Management of Conductive hearing loss due to Adhesive Otitis media with Ayurveda: A Case report. Int. J AYUSH CaRe. 2018; 2(4): 19-25.