

A Rare Case of Dextrocardia with Situs Inversus- Clinical Images

Monica Shrestha^{1*}, Tukaram Dudhamal²

¹ Assistant Professor, Dept. of Shalyatantra, Harmony Ayurveda College and Hospital, Ferozpur, Punjab, India

² Associate Professor and I/C HOD, Dept. of Shalyatantra, IPGT&RA, Gujarat Ayurveda University, Jamnagar, India

Case details:

Dextrocardia with Situs inversus is characterised by abnormal positioning of heart and viscera. In this condition visceral organs are mirrored i.e. liver is towards left side and spleen is on the right side (situs inversus). In addition to that apex of heart is towards the right side (dextrocardia). ^[1] The patient remains undiagnosed because they are usually asymptomatic and lead a normal life. A 30 year old female patient came to outpatient department (OPD) with complains of boil at anal region. Patient had no history of any other medical or surgical illness and she had a normal delivery one year back. On examination the patient was diagnosed as a case of subcutaneous fistula. Patient was advised to undergo surgery for fistula after routine investigation (Chest X-ray- PA view, X-ray abdomen in standing posture, ECG and blood test- haematological and biochemical). Chest X-ray showed Dextrocardia (Fig- 1), ECG showed inversion in the waves. X-ray abdomen revealed that the viscera were reversed that is liver was on the left side, fundal gas shadow was seen on the right side (Fig- 2). USG report confirmed situs inversus. So, the patient was diagnosed as the case of Dextrocardia with situs inversus. Patient was operated for fistula under spinal anesthesia and cured completely and enjoying her normal life after surgery. This patient was a normal healthy female with no history of any medical illness during investigation for the medical fitness she was diagnosed with dextrocardia with situs inversus. ^[2] This case report aimed at presenting a very rare condition with the clinical images.

References:

1. <https://emedicine.medscape.com/article/413679-overview> [Last Assessed on 2019 July 28]
2. Gentile B, Tighe D, Situs inversus totalis - case report, The new England journal of medicine : 2019;380.

Received: 20.08.2019

Revised: 22.09.2019

Accepted: 29.09.2019



*CORRESPONDING AUTHOR:

Dr. Monica Shrestha

Assistant Professor, Dept. of Shalyatantra,
Harmony Ayurveda College and Hospital,
Ferozpur, Punjab, India

Email: shresthamonica33@gmail.com

Clinical Images:

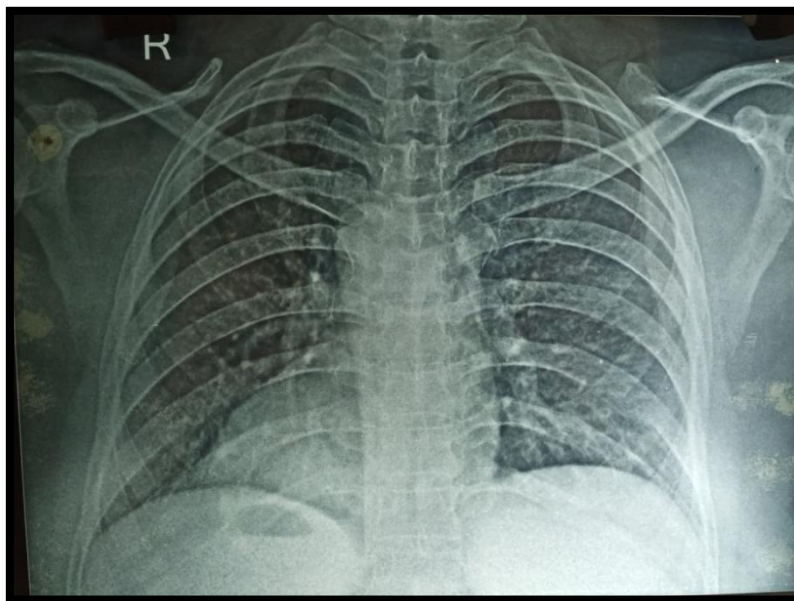


Fig-1: Chest X-Ray PA view showing dextrocardia

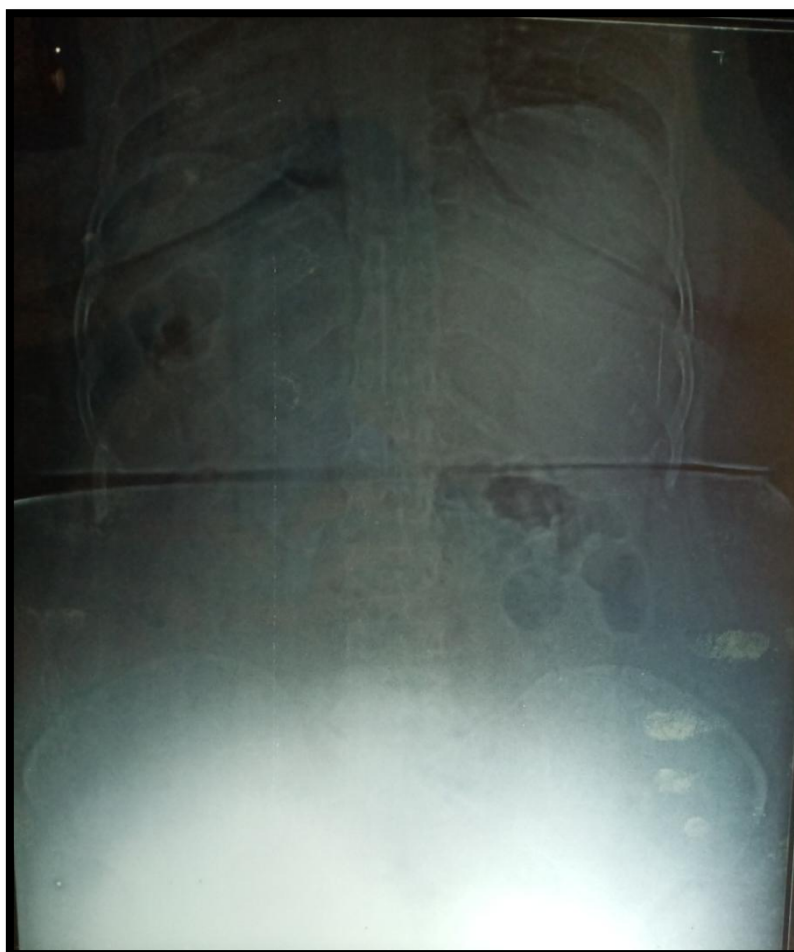


Fig-2: X-ray abdomen standing showing fundal gas shadow on right