

Alopecia Areata cured with Individualized Homoeopathy Medicine – An Evidence based Homoeopathy Case Report

Dr. Sivakumar K.*

Research Officer (H)/Scientist-1, Clinical Research Unit for Homoeopathy, Dimapur, Nagaland.

ABSTRACT:

Alopecia areata is an autoimmune disease affecting genetically susceptible people characterized by loss of hair in sharply defined areas of skin. Alopecia areata affects all ages people and affects 1 to 2% of the human population. Alopecia areata is still a puzzle to many dermatologists due to its unpredictable response to medications like the recurrence of complaints, variation in clinical presentations like alopecia totalis, alopecia universalis, ophiasis. A 15 years old boy presented with clinically diagnosed Alopecia areata condition at OPD, Govt Homoeo Dispensary, Panjal, Kerala. The patient was treated with individualized homeopathic medicine for 1 year. There was a complete cure of Alopecia areata without any side effects and recurrence of lesions. Individualized homeopathic medicine selection after considering totality of symptoms proves worth. This case report supports the positive role of homoeopathy in treating alopecia areata.

KEY WORDS: Alopecia, Atopy, Homoeopathy, Individualization, Phosphorus. Selenium.

Received: 17.01.2022 Revised: 16.02.2022 Accepted: 01.03.2022 Published: 20.03.2022

Quick Response code



*Corresponding Author:

Dr. Sivakumar K.

Research Officer (H)/Scientist-1, Clinical Research Unit for Homoeopathy, Dimapur, Nagaland.

E-mail : drshivasree@gmail.com

INTRODUCTION:

Alopecia areata (AA) is an autoimmune disorder characterized by patches of non-scarring hair loss affecting scalp and body hair. This condition may affect the eyebrows, eyelashes and beard. [1] AA is the most prevalent autoimmune disorder and the second most prevalent hair loss disorder after androgenetic alopecia. The lifetime incidence of AA is approximately 2% worldwide. [2] The disease may be limited to one or more discrete, well-circumscribed, round, or oval patches of hair loss on the scalp or body. But in some cases, it may affect the entire scalp is

known as alopecia totalis or the entire body is known as alopecia universalis.[3] In diffuse alopecia areata cases prognosis may be bad.[4] In most patients the onset is within the first 3 decades of life, although alopecia areata can start any age. The sex incidence is probably equal. [5] Psychosocial stress has been reported to play a role in the onset and/or exacerbation of alopecia areata.[6] AA is associated with psychiatric and medical comorbidities including depression, anxiety, and several autoimmune disorders. Diagnosis is made by Clinical history, the pattern of alopecia, clinical examination, in diffuse cases,

trichogram and biopsy are advised. [7] In conventional medicine there is no preventative therapy or cure and it is increased global burden of disease, a systematic review on epidemiology and burden of alopecia areata had concluded. Whereas the homeopathy system of medicine will offer promising results in the treatment of alopecia areata with individualized homeopathic medicine, and also it can treat root cause to prevent recurrence and ensure healthy hair growth. This case report further provides evidence for individualized homeopathic medicine effectiveness in the treatment of alopecia areata.

CASE REPORT:

A 15 years old boy consulted at OPD of Govt. Homoeo Dispensary, Panjal, Kerala, with multiple hair loss patches over the scalp. Complaints started at the age of 10 years as loss of hair over vertex region of the scalp, after that he was consulted a dermatologist, and taken some treatment, initially there was some regrowing of hair but after that, he had developed 2 more other lesions in occiput and frontal region of the scalp. The boy had a history of atopy in childhood, his skin was sensitive and dry, and he had dandruff with itching scalp. His parents were concerned about his condition tried conventional treatments but could not get benefit much. On local examinations, hair loss patches were present over the scalp, multiple patches on vertex, frontal, and occiput region, and on close examination, there were short broken hair present at the edge of patches which are known as 'exclamation mark'. With the history, pattern of hair loss and pathognomonic feature of exclamation mark on examination lead the diagnosis of alopecia areata. 15th October 2019 was his first consultation, specific remedy for alopecia areata *Selenium 30C* was given weekly once for 1 month. But

no positive change was noted, after that detailed case taking was done. The boy was social, wants company, talkative and bold, but sensitive to trifles and offends easily, anxiety about alopecia condition, has fear of thunderstorm, average in studies, desire fish and chicken but chicken causes urticarial rashes over the skin, his perspiration was profuse which leaves yellow stains on innerwear and his thermal reaction was chilly.

METHODOLOGY/TREATMENT GIVEN:

All the symptoms obtained from detailed case taking were analysed as in table no.1, characteristic symptoms were converted to rubrics, Kent repertory was selected for repertorization, and is done through similia ultra software as in table no.2. On 20/11/2019 has been given *Phosphorus 0/3*, 1dose, OD in the morning for 1 month. Phosphorus Medicine was selected based on individualization, repertorization and in consultation with *Materia medica*. [8-9] Along with medicine diet and regimen also recommended and advised some exercises, relaxation techniques to relieve stress. On subsequent follow-ups, potency was changed based on the assessment of improvement in bald patches. Follow-up of the patient was assessed monthly or as required. The date-wise detailed follow-ups are summarised in Table no.3. No adverse effects were noted during the period treatment.

RESULTS:

The bald patches on the head showed new hair growth. Initially, *Phosphorus 0/3* showed improvement. However, much significant improvement was observed with higher potency *Phosphorus 0/6*, *0/12*. Bald patches on the head completely disappeared within 1 year of homeopathic treatment (Figures 1-3).

Table 1: Analysis of Symptoms:

Mental Generals	Physical Generals	Particular/Disease Symptoms
Social and Talkative	Desire Cold Drinks	Hair loss Patches
Oversensitive	Desires fish	Dandruff
Desires company	Desire Chicken	Urticaria < Chicken
Fear of Thunder storm	Profuse perspiration	

Table 2: Repertorization Chart: (Kent Repertory was used since enough mental and physical generals available in case) ^[10]

Similimum Ultra - [Repertorisation-Totality Method]

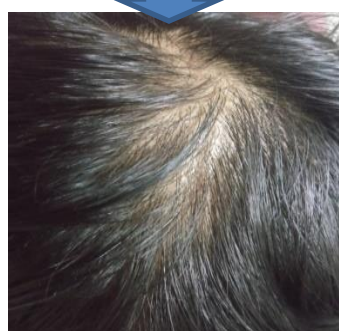
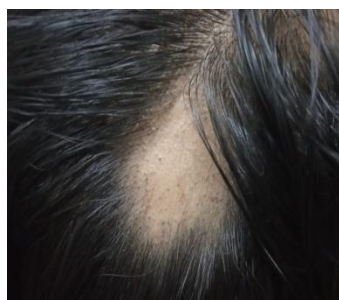ShowRepertorisationHelp

Table 3: Timeline Including Follow Up of the Case:

Date	Complaints	Prescription	Remarks
20/11/2019	Hair loss patches multiple, Sensitive skin, urticaria.	<i>Phosphorus</i> 0/3, 30doses, OD for 1month.	To repeat daily for fasten the cure.
18/12/2019	Hair loss patches same as previous. Dandruff disappeared, generally better.	Repeat Rx for 1 month.	Patient was generally better.
21/01/2020	Small hair growth started in hair loss patches. Dandruff also disappeared.	<i>Phosphorus</i> 0/3, 30doses, OD for 2months.	Hair growth started, so repeated same prescription.
25/03/2020	Hair growth standstill otherwise patient was better.	<i>Phosphorus</i> 0/6, 30doses, OD for	Improvement standstill, Potency

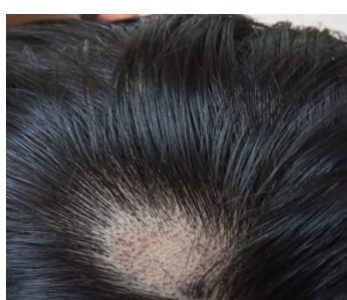
		1month	Increased.
23/04/2020	Visible hair growth seen in hair loss patches.	Repeat Rx for 2 months.	Expected improvement.
30/06/2020	Moderate hair growth in all patches	Repeat Rx for 2 months.	-do-
28/08/2020	Hair growth was standstill.	<i>Phosphorus</i> 0/12, 30doses, OD for 1month	Improvement standsill. Potency Increased.
30/09/2020	All patches filled with thick density of hair	Repeat Rx for 2 months.	Total near cure of Alopecia areata.
25/11/2020	Normal density of hair growth, no other complaints except frequent coryza, running nose.	<i>Tuberculinum</i> 1m, 1dose, SL for 30days	Complement remedy to remove tendency to cold.
29/12/2020 to 22/11/2021	Patient was under my consultation for various minor ailments during this period.	Had given indicated medicines for existing ailments.	Observed one year, no recurrence of patches developed.

Fig-1
Before Treatment



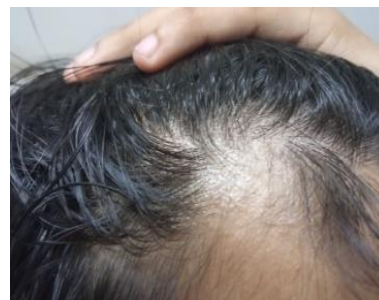
After Treatment

Fig-2
Before Treatment



After Treatment

Fig-3
Before Treatment



After Treatment

DISCUSSION:

Alopecia areata mostly presented as one-sided local disease. The patient was presented with multiple hair loss patches over the scalp. This case was treated with individualized homoeopathic medicine, the case was cured with complete regrowth of

hair in bald patches without any recurrence in the follow up period. As there is no effective treatment in modern medicine, mainline treatment is tropical immunotherapy in diffuse cases, intralesional corticosteroids in localized hair loss patches.^[11] Willemsen et al used

hypnosis to treat alopecia areata.^[12] A case study reported a positive role of Homoeopathy when individualized medicine used in treating AA.^[13] In this case after careful case taking and repertorization, in consultation with materia medica *Phosphorus* was selected. Psychological stress has been reported to play a role in the onset and/or exacerbation of alopecia areata. Patients whose alopecia is stress-reactive may suffer from depressive illness, a potentially important consideration in the overall management of such patients. In this case along with medicine, diet and regimen including stress relieving activities also advised. This case showed marked improvement which proved correct selection of medicine. In this case, since the patient suffering from complaints for 5 years, was anxious and worried about disease and desperately desire for regrowth of hair in bald patches. So Millesimal scale of potency was used to repeat the medicine as required and to fasten the cure. 50 millesimal scale of potency is a new dynamization scale of method introduced by Dr. Samuel Hahnemann in 6th edition of organon of medicine, in which produce medicines highest development of power and mildest action, which however, if well chosen, touches all suffering parts curatively, in acute cases may be repeated in short intervals, in chronic cases it is best to begin with lowest degree of dynamization and when necessary advance to higher and may be repeated as required to fasten the cure, by that such a local disease will often then disappear in a wonderful way.^[14] So in this case treatment started with *Phosphorus* 0/3, daily one dose in morning and slowly increased to 0/6 and 0/12 potency for achieving speedy cure. As expected, total cure was achieved in 1 year of time. By that this case showed effective role of homoeopathic medicine in treating of

Alopecia areata when prescribed on homoeopathic principles. Since it is a single case study and Alopecia areata is associated with a variable and unpredictable remission, well-designed randomized control studies may be taken up for providing gold standard evidence.

CONCLUSION:

Homoeopathy is a system of medicine based on the principle of "Similia Similibus Curentur". It treats patient as a whole and not just symptoms. After careful case taking, analysis and repertorization done systematically, then the selection of the right medicine with a suitable scale of potency and dosage results in remarkable cures. Complete hair re-growth and without any recurrence of bald patches in observation period is documentary evidence. This case showed a positive role of Homoeopathy in treating Alopecia areata.

LIMITATION OF STUDY:

However, as this is a single case study and Alopecia areata is associated with a variable and unpredictable remission, well-designed randomized control studies may be taken up for scientific validation of results.

CONSENT:

I hereby certify that the patient has been given consent for his images and other clinical information to be reported in the journal. The patient understands that his name and other contact details will not be published, and due efforts will be made to conceal his identity, but anonymity cannot be guaranteed.

ACKNOWLEDGEMENT:

I sincerely thankful to Dr. Chaturbhuja Nayak, former Director General, CCRH, Ministry of Ayush, Govt. of India for valuable guidance in scientific writing. We

acknowledge the support and cooperation of staff at Govt. Homoeo Dispensary, Panjal.

REFERENCES:

1. Davidson's Principles and practice of medicine, edi. Nicholus AB, Nicki RC, Brain RW, 20th edition, Churchill Livingstone/Elsevier, Edinburgh;2010: p1278.
2. Alexandra C Villasante Fricke AC, Miteva M. Epidemiology and burden of alopecia areata: A systematic review. Clin Cosmet Invest Dermatol: 2015;8: 397-403.
3. Arthur R, Rook's textbook of dermatology, Edi. Tony, Stephen b, Neil c, Christopher G, Eighth edition, John Wiley Sons, 2010; Vol 4, Chap.66, pp. 66.31-66.38.
4. Shivakumar K, Hair problems answered with homoeopathy, Alopecia Areata, B.jain: New Delhi; 2016. p-46-75.
5. Klaus W, Lowel AG, Stephen IK, Barbara AG, Amy SP, David JL, Fitzpatrick's dermatology in medicine, 7th edi, Mc graw hill, USA; 2008: Vol 1, p762.
6. Gupta MA, Gupta AK, Watteel GA Stress and alopecia areata: a psychodermatologic study, Acta Dermato-venereologica.1997, 77(4): 296 -298.
7. Rivitti EA. Alopecia areata: A revision and update. Bras Dermatol 2005; 80:57-68.
8. Boericke W. Pocket manual of homoeopathic materia medica and repertory. B. Jain, New Delhi; 1994. p- 507.
9. Allen HC, Key notes and characteristics with comparisons of some of the leading remedies of the materia medica with bowel nosodes, Eighth edition, B.Jain: New Delhi; 2002.p-219.
10. Kent JT, Repertory of the homoeopathic materia medica, B.jain: New Delhi; 57th impression, 2019.p-63.
11. Harries MJ, Sun J, Paus R, King LE Jr. Management of alopecia areata. BMJ 2010;341:c3671.
12. Willemsen R, Vanderlinden J, Deconinck A, Roseeuw D. Hypnotherapeutic management of alopecia areata. J Am Acad Dermatol 2006; 55:233-7.
13. Shivadikar AP. Evidence- based homoeopathy: Case report of alopecia areata in an 11 year old boy. Indian J Res Homoeopathy 2019;13:251-5.
14. Hahnemann CFS, Organon of medicine, 6th edition, B.jain Publishers, New Delhi; 2008: Aph270, p221-223.

CONFLICT OF INTEREST: Author declares that there is no conflict of interest.

GUARANTOR: Corresponding author is guarantor of this article and its contents.

SOURCE OF SUPPORT: None

HOW TO CITE THIS ARTICLE:

Sivakumar K. Alopecia Areata cured with Individualized Homoeopathy Medicine – An Evidence based Homoeopathy Case Report. Int. J. AYUSH CaRe. 2022; 6(1):70-75.