

Treatment of Warts through Homeopathy protocol- A single Case Report

Rajesh Kumawat,¹ Neeta Sharma,² Yashasvi Shakdvipiya,³ Diksha Agrahari ⁴

¹Associate Professor, Human Physiology and Biochemistry, University College of Homoeopathy, DRSRAU, Jaipur, Rajasthan, India

²Assistant Professor, Dept. Of Surgery, Homoeopathy University, Jaipur, Rajasthan, India

³Associate Professor, Dept. Of Repertory, Homoeopathy University, Jaipur, Rajasthan, India

⁴PG Scholar, Dept. of Organon of Medicine and Homoeopathic Philosophy, Homoeopathy University, Jaipur, Rajasthan, India

ABSTRACT:

Warts are benign tumours caused by DNA viruses i.e. Human papilloma viruses. Overall prevalence is known to be around 7-10% of the population. It is essential to get rid of the disease as soon as possible because the affected person suffers from cosmetic disfigurement with pain and remains as a potent source of transmission to others leading patients to go for drastic measures such as cauterisation and various oils and ointments costing them a huge sum, homoeopathic drugs, on the other hand are cost effective and easy to take having no side effect. A case of multiple filiform warts on face of a 40 years old man responded commendatory with individualised medicine *Causticum* in 1M potency followed by 10M potency. Photographic evidence was maintained. The case report suggests that a single medicine in higher potency have effective role in treatment of case of wart when generals are matching with remedy.

KEYWORDS: *Causticum*, Filiform Wart, Homoeopathy.

Received: 03.05.2022 Revised: 30.05.2022 Accepted: 19.06.2022 Published: 03.07.2022

Quick Response code



*Corresponding Author:

Dr. Yashasvi Shakdvipiya

Associate Professor, Dept. Of Repertory,
Homoeopathy University, Jaipur, Rajasthan, India

E-mail : yashasvi119@gmail.com

INTRODUCTION:

Warts are commonly known as benign tumors that commonly involve the skin and other epithelial tissues, caused by DNA viruses i.e. Human papilloma viruses. [1] The diagnosis is based on clinical examination and usually straight forward by visual inspection. Indications for treatment include pain, interference with function, cosmetic

embarrassment, and risk of malignancy.[2]

Clinically, three types of warts are encountered in dermatology practice – common warts, plantar warts and genital/anal warts. They may be soft, hard, rough, smooth, scaly, flat etc. which are mainly determined by the type of the virus and the location.[3] Though sometimes, it is a self-limiting disease but on an average it

takes about 1-2 years for resolution,^[3] during which the affected person suffers from cosmetic disfigurement. Thus it is essential to get rid of the disease as soon as possible.

CASE REPORT:

The reported case is 40 years old, vegetarian, male, businessman by profession, belonging to a middle socio-economic family, residing in urban area who came to our OPD of Dr. M.P.K. Homoeopathic Medical College, Hospital and Research Centre, Sindhi Camp (A Constituent College of Homoeopathy University), Jaipur, Rajasthan, India on 03/08/2020 with the following complaints of multiple filliform warts on face since three and half years with slight itching when exposed to dust and sun light. Largest wart up-to 0.9 cm, rest are small. Rough skin around warts with spiky appearance and smooth surface.

Associated complaints are intense pain in both lower limbs for last 1 year with > by warm water application++, hot fomentation++

Ringing in both ears for last 6 months with sensation of ringing sounds which lasts for 4-5 seconds only.

History of presenting complaints: Patient was apparently well three and the half years back. One day patient noticed a red, small, wart on chin area and almost after half or 1 month second wart was noticed in the same area. Pain in lower limbs started after typhoid fever and ringing in ears started suddenly one day. No causation identified.

Treatment History: For warts, he took ayurvedic treatment for 1 month. No relief. After that started taking home made remedies with no improvement and warts were increasing in numbers. No treatment

taken until now for pain in lower limbs and ringing in ears.

Patient as a whole:

- Appetite- 3 meals/day, 2-3 chapati/meal, satisfactory
- Thirst- Thirsty, drinks cold water of 1-2 glass of water at interval of 1-2 hour. Highly desire for cold water++ (matke ka paani) even in winter season
- Desire – Salty food ++, he always craves for salty food.
- Aversion – Sweets++
- Stool- Constipated for 10-12 years. Goes for motion daily but passes hard stool. Taken Ayurvedic and home- made remedies for constipation. Got relieved only for sometimes but complaints appear as treatment stops. Now patient is habituated to constipation.
- Perspiration- Generalized without any peculiar odor.
- Any tendency/suppuratation- Suffers from cold easily at slightest change of weather.
- Addiction- Tea. Causes headache if does not take. 6-8 cup/day
- T/R- Ambithermal

Past history: Had typhoid 2 years back. Took allopathic treatment and got relieved.

Family history:

- Mother- Diabetes mellitus for 8 years, taking allopathic medicines
- Father- Hypertensive for 12 years, taking allopathic medicines
- Wife- Healthy and alive
- Children- Healthy and alive

Mental generals: Highly anxious for future that what will happen? How my children will survive? as he has small business. Sometimes unable to earn sufficient money. Due to Covid, business did not run properly.

He is facing financial problems. (Patient was continuously talking about future only). Emotionally very weak. Gets emotional easily and over small matter. He may cry in front of anyone. Forgets easily. (forgets keys of shop, well known streets, names etc.) He has fear of darkness. Whenever electricity goes off, he usually gets panicked. Can't sit in dark room.

General examination: Conscious
General appearance (Expression and look)- Patient is apparently healthy looking

Height – 152cm Weight – 68 kg Built – Lean, thin. Blood pressure- 140/80 mmHg
Temp- Afebrile. Pulse- 80/min
Resp rate - 18/min Complexion – Wheatish
Tongue – White coated Skin – Dry

Local examination: multiple, skin colored, spiky in appearance, smooth surfaced, cylindrical shaped warts are seen on face only. (Figure 1-3).

Provisional diagnosis – Filiform warts on the basis physical examination.^[3]

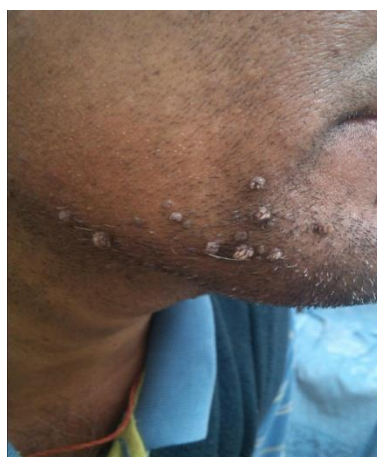

Figure 1- Multiple warts on lower right side of face, taken on 03/08/2020

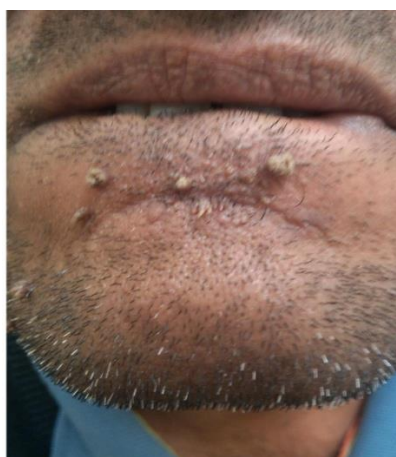

Figure 2- Multiple warts on chin taken on 03/08/2020

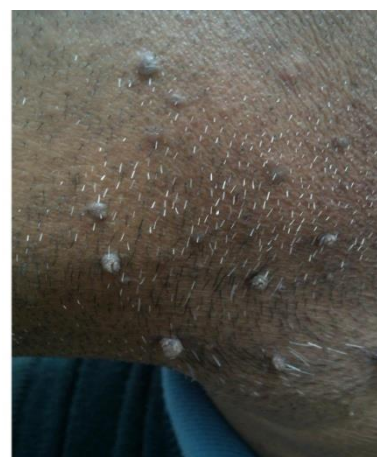

Figure 3- Multiple warts on left side of face, taken on 03/08/2020

Table-1: Case processing:

1. Mentals			
	Evaluation	Common/Uncommon	Miasmatic Analysis 4-6
Anxiety about future	3+	Uncommon	Psora
Weakness of memory	3+	Uncommon	Psora-Sycosis
Cry Easily	3+	Uncommon	Psora
Fear of dark	3+	Uncommon	Psora
2. Physical Generals			
Thirst-thirsty	2+	Uncommon	Sycotic-syphilis
Desire for cold water	2+	Uncommon	Sycotic-syphilis
Desire- salt	3+	Uncommon	Sycotic-syphilis

Aversion-sweet	3+	Uncommon	Sycotic-syphilis
Stool-constipated	2+	Uncommon	Psora
Hard stool	2+	Common	Psora
Tea addiction	2+	Uncommon	Psora-Syphilis
3. Particulars			
Warts on face	2+	Common	Psora-Sycosis
Pain in lower limbs > hot fomentation	2+	Common	Psora
Tendency to take cold at slightest change of weather	3+	Uncommon	Psora-Syphilis
Ringing in ears	2+	Common	Psora

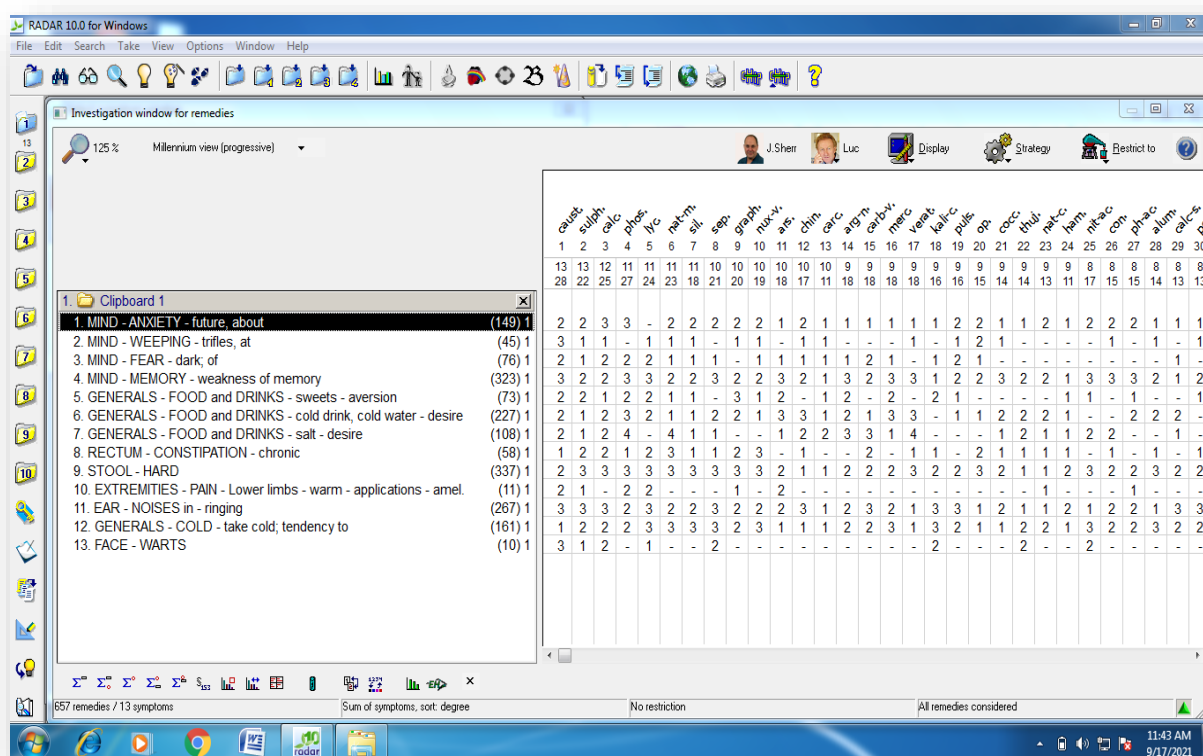


Figure 4- Repertorization sheet from RADAR 10.0 version

TIME LINE AND FOLLOW UP:

Table-2: Treatment Protocol:

Date	Symptoms	Prescription	Justification ^{4, 10-12}
17/08/2020	No apparent change was seen in the lesions. Bleeding while shaving occurred once last week. Slight relief in pain in lower limbs.	Placebo 30 three times a day for 14 days	Although no changes observed in lesions initially but after considering the action of medicine, only phytum is given.
31/08/2020	No change was seen in the lesions. > ++ in pain of lower limbs. Ringing in ears same.	Placebo 30 three times a day for 14days	Placebo is given again as slight improvement in other symptom was observed.
14/09/2020	Lesions seems to be drying up slightly. > ++ in pain of lower limbs. Ringing in ears same.	Placebo 30 three times a day for 14days	Changes observed and placebo was given.
28/09/2020	Smaller lesions have dried up and a 2-3 disappeared, but no apparent changes in a few lesions. No itching in lesions while exposure to sun. > +++ in pain of lower limbs. Slight relief in ringing of ears.	Placebo 30 three times a day for 14days	Changes observed and placebo was given.
12/10/2020	Lesions drying up. Appearing smaller in size.	Placebo 30 three times a day for 14days	Changes observed and placebo was given.
26/10/2020	> +++ in pain of lower limbs. Relief in ringing of ears. But no further improvement in lesions.	Placebo 30 three times a day for 14days	Changes observed and placebo was given.
09/11/2020	Status quo.	<i>Causticum</i> 10M/1dose <i>Rubrum</i> 30 three times a day for 14days	Potency increased in case of no further improvement.
23/11/2020	Lesions drying up. Markedly improvement in pain of lower limbs and ringing of ears. (figure 5-7)	Placebo 30 three times a day for 14days	Changes observed and placebo was given.
07/12/2020	Some lesions and ringing of ears disappeared.	Placebo 30 three times a day for 14days	Changes observed and placebo was given.
21/12/2020	Lesions completely resolute, the beard area looks clean now. Gets	Placebo 30 three times a day for 14days	Changes observed and placebo was given.

INTERNATIONAL JOURNAL OF AYUSH CASE REPORTS (IJA-CARE)

	anxious occasionally when thinks too much. Otherwise working properly and peacefully. Concentrates on work and tries to remember which is not easy before. Trying to overcome his fear and anxiety.		
04/01/21	Beard area is clean. no new lesion found. Patient is feeling better. No other new complaints. (figure 8-10)	Placebo 30 three times a day for 14days	Changes observed and placebo was given



Figure 5: Lesions drying up (taken on 23/11/2020)

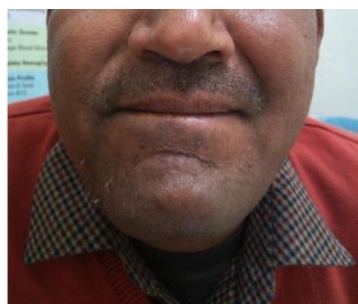

Figure 6: Lesions drying up (taken on 23/11/2020)

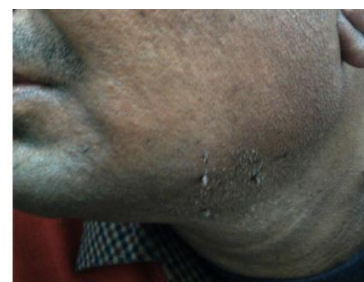

Figure 7: Lesions drying up (taken on 23/11/2020)

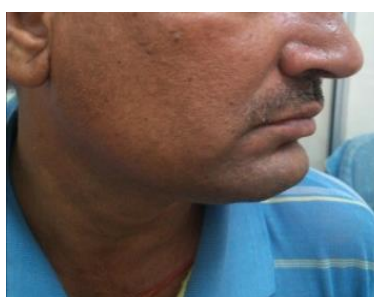

Figure 8: Lesions disappeared. (taken on 04/01/2021)

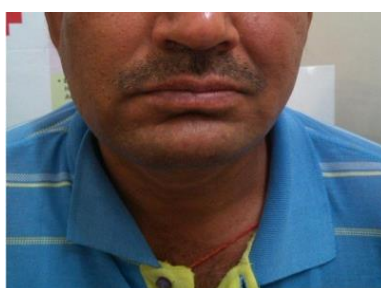

Figure 9: Lesions disappeared. (taken on 04/01/2021)

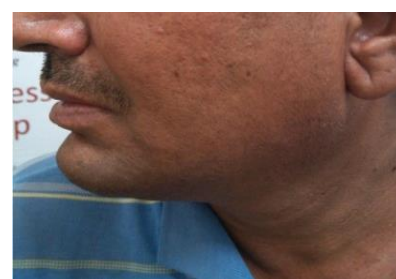

Figure 10: Lesions disappeared. (taken on 04/01/2021)

Pre - dominant miasm - Mix miasmatic but predominantly Psora.^[4-6]

Repertorisation- As the generals were marked, this case was repertorised with the help of the Synthesis repertory from RADAR 10.0 version.^[7] (Figure 4)

Selection of remedy- *Causticum* was selected on the basis of repertorisation (Figure-4) and after the consultation of materia medica, considering the symptom similarity.^[8, 9]

Selection of potency and dose - 1 dose (Stat) of *Causticum* 1M was prescribed. (According to principles of single dose of similimum in higher potency if symptom similarity is higher.^[4, 10-12]

Justification of repetition – has been done when requires, according to principles.

03/08/20: *Causticum* 1M / 1 dose / stat
Rubrum 30 / TDS × 14 days.

General management –

- Avoid touching the lesions by hands.
- Don't apply any ointment.
- Cover face properly if sun exposure causing itching
- Don't try to pluck it.

DISCUSSION:

In this case report *Causticum* was prescribed as individualized homeopathic medicine on the basis of totality of symptoms and repertorization.^[8, 9] Homoeopathic literature narrates *Thuja occidentalis* as most cited remedy that comes up in cases of warts,^[9] but it is also observed that *Thuja* essentially doesn't work in every case, the medicine selected must be the similimum (aphorism 147) in order to attain permanent cure (aphorism

2).^[10,13] Apart from *Thuja* there are many other medicines which are used therapeutically i.e. on the basis of location, presentation and type of the warts.^[8, 9] But in this case, symptoms were analysed and medicine was selected on the basis of totality and individualization of the case (aphorism 7).^[10] Considering the law of similar (aphorism 26)^[10] and action of *Causticum* on skin, made it the best suitable medicine in this case to cure.^[8, 9, 13, 14] Both *Thuja* and *Causticum* have been reported in the literature as useful medicines for the treatment of warts, but the selection of *Causticum* depended upon the presenting totality including other general complaints present in the persons and overall constitution. The patient was followed-ups for the six months with no recurrence. This study showed wonderful result of higher potency of well selected individualised homoeopathic medicine. Many RCT and case reports suggest role of *Causticum* as curative medicine for treatment of warts.

CONCLUSION:

It can be concluded that homeopathic treatment for warts is constitutional as there are very few symptoms based on the location, morphology, and sensation of the warts. Homoeopathic medicines in higher doses bring result in short duration of treatment period.

LIMITATION OF STUDY:

As a single case report, results cannot be conclusive for generalisation.

PATIENT'S CONSENT FOR PUBLICATION:

The written consent has been obtained from patient for management and publication of images but identity of patient has not disclosed.

REFERENCES:

1. Warts: Overview [Internet]. Cologne, Germany: Institute for Quality and Efficiency in Health Care; 2019 [cited 11 November 2020]. Available from: <https://www.ncbi.nlm.nih.gov/books/NBK279586/>
2. Sekhar Namburi U, Babu G, Omprakash. A review on management of warts in Ayurveda. *AYU (An International Quarterly Journal of Research in Ayurveda)* 2011;32(1):100.
3. Khanna N. Illustrated synopsis of dermatology & sexually transmitted diseases. 5th ed. Reed Elsevier Pvt. Ltd, New Delhi. 2016. P-29.
4. Hahnemann S. The Chronic Diseases: Their peculiar nature and their homoeopathic cure sed. B Jain Publishers (p) Ltd, New Delhi. 1995. P-239.
5. Roberts H. The principles and art of cure by homoeopathy. B Jain Publishers (P) LTD; Reprint 2004. Pp 236
6. Banerjee S. Miasmatic diagnosis. New Delhi: B. Jain; 4th ed. 2011. Pp 175.
7. Rapid Aid to Drug Aided Research 10.0.28 software version, RADAR repertory programme; 2007
8. Kent, James Tyler. Lectures on Materia Medica. Delhi, India: B. Jain Publishers, 2004. Pp 398
9. Boericke, W. Boericke's New Manual of Homeopathic Materia Medica with Repertory. 9th ed. B. Jain Publishers (P) LTD. New Delhi. 41st imprint 2018. Pp 161, 565.
10. Sarkar BK, Majumdar JN, Dudgeon RE. Organon of Medicine by Samuel Hahnemann. Reprint edition. Birla Publications PVT. LTD; Delhi. 2006-2007. Pp 163, 254-255.
11. Close S. The genius of homoeopathy lectures and essays on homoeopathic philosophy Reprint ed. B Jain Publisher (P) Ltd 2008. Delhi. Pp 183, 190
12. Kent JT: Lectures on Homoeopathic Philosophy. 5th ed. Reprint, B Jain Publishers (P) Ltd., 1989. Pp 67.
13. Biswas B, Roy PS, Mandal S, Roy P. Four cases of warts treated by individualized homoeopathic medicine - a clinical case study. *J Intgr Stand Homoeopathy* 2022;5:9-18.
14. Shaikh MI. Case studies for treatment of warts with Homoeopathy. *Indian J Res Homoeopathy* 2016;10:272-8

CONFLICT OF INTEREST: Author declares that there is no conflict of interest.

GUARANTOR: Corresponding author is guarantor of this article and its contents.

SOURCE OF SUPPORT: None

HOW TO CITE THIS ARTICLE:

Kumawat R, Sharma N, Shaktvipyaya Y, Agrahari D. Treatment of Warts through Homeopathy protocol- A single Case Report. *Int. J. AYUSH CaRe.* 2022; 6(2):219-226.