

***Ksharasutra* ligation in the management of fourth degree multiple haemorrhoids in single sitting – A case report**

Bijendra Shah, ¹Shailly Maurya¹, Tukaram Dudhamal²

¹MS (Ayu) Scholar, ²Associate Professor, Department of Shalya Tantra, Institute for Post Graduate Teaching and Research in Ayurved, Gujarat Ayurveda University, Jamnagar, Gujarat, Pin-361008, India

Abstract

Haemorrhoids also known as piles are inflamed or swollen anal cushions. They are classified in four categories. When the haemorrhoidal mass remains protruded outside anus and cannot go inside the anal canal even with help of fingers is said to be fourth degree pile mass. *Ksharasutra*(medicated thread) treatment is in practise for *Arsha(piles)*, *Bhagandara(Fistula)*, *Nadivrana(sinus)*and *Arbuda(cancer)*and other pathologies mentioned in Ayurvedic texts. Due to its potential healing, sclerosing and antibacterial property it is found very effective in the treatment of piles. In this study, a 36-year-old patient with the complains of bleeding per rectum and protrusion of mass per ano having pile mass at 3 ,5, 7, 11 o' clock position. His pile mass was ligated with *Ksharasutra*.*Ksharasutra* (medicated thread) ligation on all pile mass was done under spinal anaesthesia. The dressing was done daily with *Panchawalkal Kawath* (decoction of five herbs) and *Jatyadhi Tail* (Medicated oil). Complete sloughing of pile mass was noted in 5 days and healing of ulcer was achieved by 30 days along with resolution of all symptoms. The patient was relieved from all symptoms within two weeks. No complications were reported after the procedure.

Key words: *Arsha*, Interno-external piles, *Ksharasutra*, Haemorrhoids.

Received: 13.06.2018

Revised: 20.06.2018

Accepted: 26.06.2018



CORRESPONDING AUTHOR

Bijendra Shah

MS (Ayu) Scholar, Department of Shalya Tantra
IPGT&RA, Gujarat Ayurveda University, Jamnagar,
Gujarat, India

Email: bijendrashah17@gmail.com

Mobile: +919801341818

Introduction:

Haemorrhoids have plagued human civilization since ages. It occurs frequently in adult general population. Both genders report peak incidence around 45 to 65 years. Notably, a considerable amount of people do not complain about the symptoms.^[1] Haemorrhoids are dilated veins in anal canals that lie along the anal canal in three columns- left lateral, right posterior and right anterior positions.^[2] In Ayurveda haemorrhoids are correlated with *arsha*. *Arsha* is considered under eight graves' disease (*Ashtamahagada*) by *Acharya Sushruta*.^[3] In modern practice there are different modalities available for the treatment of haemorrhoids like cryosurgery, haemorrhoidectomy, coagulation therapy, infra-red coagulation, rubber band ligation, stapled haemorrhoidectomy, sclerosing injection therapy etc. which has its own merits and demerits. There may be complication like incontinence, haemorrhage and anal stricture.^[4]

Though there are various treatment available for the treatment but the options are narrowed down due to the effectiveness of treatment. *Ksharasootra* (medicated thread) ligation is an ayurvedic technique for the treatment of disease like *Arsha* (piles), *Bhagandara* (Fistula), *Nadivrana* (sinus) and *Arbuda* (cancer) and various other disease. The *Ksharasootra* treatment is found to acceptable as well as suitable as compared to prevalent modern practices due to its mechanical pressure and chemical cauterization effect.^[5]

Case History:

A 36 year old male patient visited the OPD with the complaints of protrusion of mass per rectum since last 3 months along with bleeding P/R after defecation in syringing manner on and off for 4 months. He was also having pain in ano after defecation since 15 days. On examination there was fourth degree pile mass at 3, 7 and 11'o clock position.[Fig-1] He was admitted in IPD and routine laboratory investigations for blood, urine, stool, radiological test were found normal and thus was planned for *Ksharasootra* (medicated thread) ligation under spinal anaesthesia.

Materials and Methods:

Standardised *Apamarga Ksharasootra* (medicated thread) which has 11 coatings of *Snuhi Ksheera* followed by seven coatings of *Snuhi* and *Apamarga Kshara* followed by *Snuhi Ksheera* and *HaridraChurna*. All together, 21 coatings are done for the preparation of *Apamarga Ksharasootra*.

Pre-operative procedure:

Inform written consent was taken after describing the procedure to the patient. Injection xylocaine sensitivity 2% 0.1 ml ID was done. Injection tetanus toxoid 0.5 ml IM was given as prophylactic measure. Patient was kept nil orally from 11:00 PM on the previous day of operation. Before the day of operation soap water enema was given at night and proctolysis enema was given on the day of operation in the morning on the day of operation for cleaning the operated reason.

Operative procedure:

After giving spinal anaesthesia patient was laid down in lithotomy position. Local part painting was done with betadine solution and spirit. Draping was done with sterile cut sheet. Four finger anal dilatation was done. Proctoscopy examination was done to confirm the diagnosis. At first 3 o'clock pile mass was held with pile holding forceps and external component was incised by using cutting scissors up to the level of mucocutaneous junction sparing the sphincter muscles and mucosal part. Bleeders were checked by the use of electro-cautery. Using a round body curved needle and *Ksharasootra*, pile mass was transfixed and ligated at the base of its pedicle. Along the separated part of the external component from the skin the thread was placed and reef knot was tied. In similar way 7 and 11 o'clock pile mass was transfixed and ligated. [Fig-2] After ensuring haemostasis, part was cleaned with betadine solution and finally T-bandaging was done.

Post-operative procedure:

After shifting the patient to the ward, intravenous fluid Ringer Lactate was started, followed by Dextrose Normal

Saline. Patient was continued to be kept on nil orally for further six hours. Injection Ranitidine 2cc IV was given. Antibiotic coverage was given by Ceftriaxone 1.5 gm BID and Ornidazole 500mg TDS for three days. From first post-operative day daily sitz bath with *PanchavalkalKwatha* twice a day, *TriphalaGuggulu* 500 mg TDS and *ErandaBhrishthaHaritaki* 5 gm at night with lukewarm water was advised. Dressing was done daily, along with 10 ml *JatyaditailaMatrabasti*.^[6] From the second post-operative day twisting of thread was done during dressing as the necrosis of pile mass has started.[Fig-3] Necrosed pile mass at 5, 7 and 11 o'clock got sloughed out on third post-operative day and 3 o'clock pile mass the following day. Fresh wounds were observed at the respective place of pile masses. Daily dressing and *Matrabasti* was continued for further 7 days. Thereafter anal dilatation was done with dilator no. 6 lubricated with *JatyadiGhrita* and 10 ml *JatyadiTailaMatrabasti* daily upto the period of 15 days to prevent stricture. On 30th post-operative day wounds were completely healed with no any complication like spasm or stricture. [Fig-4]

Pre and post-Operative photos of this case:

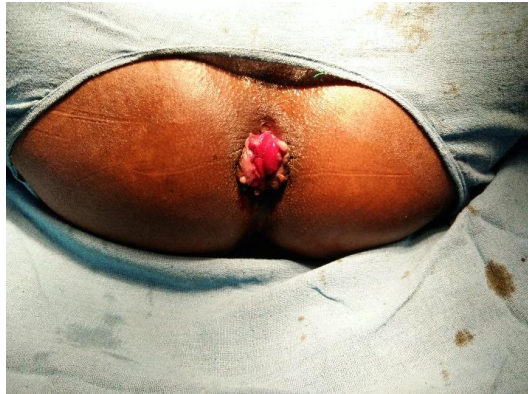


Fig-1: Pre-operative

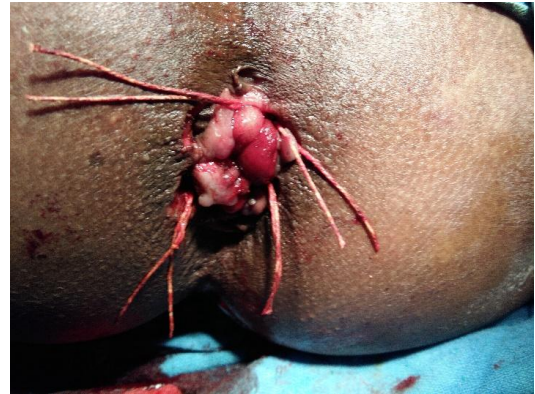

Fig-2: Post-operative

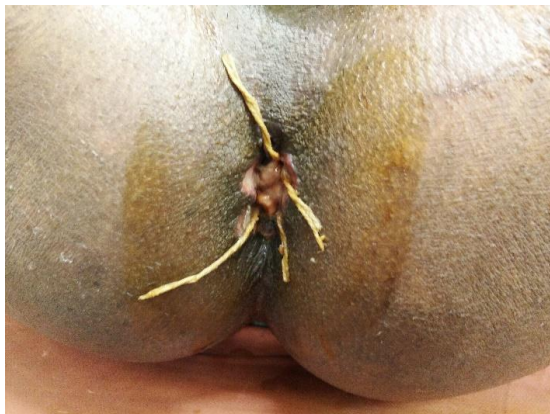

Fig-3: Post-Operative 5th day

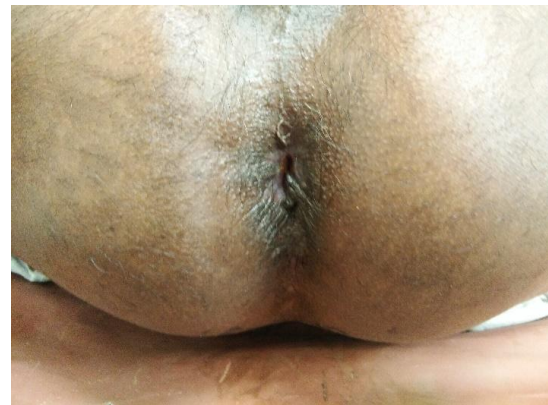

Fig-4: Post-Operative 30th day

Result & Discussion:

Acharaya Sushruta has foretold *Aushadha*, *Kshara*, *Agnikarma*, and *Shastrakarma* for the treatment of *Arshas*. *Kshara* has potential cauterization and antimicrobial property. [7] Ligation of pile mass with *Ksharasootra* not only provide the benefits of said above but also provide the mechanical strangulation which obliterates the haemorrhoidal vessels and tissues causing its necrosis and ultimately sloughing off the pile mass. *Ksharasootra* by its action as chemical cauterization and mechanical strangulation of the blood

vessel causes local gangrene of the pile mass tissue and ultimately resulting in falling out of the mass within 5-7 days. In Ayurveda it clearly mentioned that *Kshara* act as *Chhedya* (excision), *Bhedyā* (incision), *Lekhya* (scraping) and it renders chemical cauterization of tissue which facilitates cutting of tissue. Due to alkaline pH (pH-10.3) it acts as antibacterial at site of ligation. [8] Turmeric powder (*Curcuma longa*) allows minimizes reaction of caustics and helped for healing of wound. In this case no any Complications like anal

stricture, post-operative haemorrhage was observed.

Conclusion:

This study manifests that *Ksharasootra* ligation in fourth degree multiple piles in single sitting is not only effective in treating the anatomical defect but also has some superiority over modern medical practices by minimizing the post-operative complication. It is safe, simple with minimum complications and no recurrences in comparison of open or closed haemorrhoidectomy. As it is a single case study hence more research work is needed to concrete the conclusion.

References:

1. Shah B, Dudhamal TS. Tremendous Role of Ksharsutra Ligation in the Treatment of Multiples Fourth Grade Interno-External Haemorrhoids (Arsha): A Case Report, International Journal of Scientific Research; February-2018; 7(2); 729-730.
2. Goligher J, Duthie H, Nixon H. Surgery of the Anus, Rectum and Colon. A.I.T.B.S. Publishers and Distributors, New Delhi, 2004; 1:98-105.
3. Shastri A, Susruta Samhita of MaharsiSusruta, Hindi Commentary, Sutrasthana Aturopkramniya adhya, Varanasi, India, Edition-2012. P. 167.
4. Shah B, Dudhamal TS. Integrated approach in diagnosis of Ano-rectal (guda) diseases: A review. Int. J. Res. Ayurveda Pharm. 2017; 8(Suppl 3):72-76.
5. Shah B, Dudhamal TS, Prasad SM. Efficacy of Kshara Application in the

Management of Internal Haemorrhoids-A Pilot Study, Journal of US-China Medical Science 13 (2016) 169-173.

6. Shastri A. Sushruta Samhita with Ayurved Tatva Sandipika commentary, chikitsasthana, chapter 17, sutra 33, Page 81, published by Chowkhambha Sanskrit SansthanVaranasi, 13th edition, 2001.
7. Shastri A, Susruta Samhita of Maharsi Susruta, Hindi Commentary, Sutrasthana Aturopkramniya adhya, Varanasi, India, Edition-2012. P. 167.
8. Kohli K, Ali J, Ansari MJ, Raheman Z. Curcumin: A natural anti-inflammatory agent. Indian Journal of Pharmacology. 2005; 37(3):141-147.

Guarantor: Corresponding author is guarantor of this article and its contents.

Conflict of interest: Author declares that there is no conflict of interest.

How to cite this article:

Shah B, Maurya S, Dudhamal TS. *Ksharasutra* ligation in the management of fourth degree multiple haemorrhoids in single sitting – A case report - A Case Report A Case Study Int. J AYUSH CaRe. 2018; 2(2):8-12.