

Acute Pseudomembranous Candidiasis is treated Successfully with Homoeopathy- An Evidence Based Homoeopathic Case Report

Henna Khanam^{1*}, Supriya Halder²

¹ Assistant Professor, Department of Homoeopathic Materia Medica, ² Assistant Professor, Department of Anatomy, Pratap Chandra Memorial Homoeopathic Hospital & College, Kolkata, WB, India.

ABSTRACT:

The most frequent opportunistic infection caused by *Candida albicans*, Acute Pseudomembranous Candidiasis (APC) is one of the most prevalent kinds of oral candidiasis seen in clinical practice. It is diagnosed by the presence of white, curd-like plaques in the oral cavity. Patients at the extremes of age are most affected. The conventional use of anti-fungal treatment, provides but a temporary relief, before it returns worse than before. This case report brings into light the effectiveness of Homoeopathy in APC. A 72-year-old elderly man complained of a thick, yellow-white coating on his tongue, patchy white deposits in his buccal mucosa, and burning discomfort which worsened after eating or drinking for the past three weeks. Through an individualized approach, he was prescribed *Nux Vomica* 200/ 2 doses. The condition of the patient was assessed using Visual Analog Scale (VAS) score every month. The patient started showing gradual and marked improvement. Without any recurrence, the tongue's usual texture was recovered and the VAS score was reduced remarkably in 3 months. This case report thus testifies that Homoeopathy offers a great rescue in APC by giving the patient a good quality of life (QoL) and also prevents the recurrence of the disease.

KEYWORDS: Acute pseudomembranous candidiasis, Homoeopathy, QoL VAS.

Received: 20.08.2023 Revised: 19.09.2023 Accepted: 30.09.2023 Published: 02.10.2023

Quick Response code



*Corresponding Author:

Dr. Henna Khanam

Assistant Professor, Department of Homoeopathic Materia Medica Pratap Chandra Memorial Homoeopathic Hospital & College, Kolkata WB
E-mail : drhennakhanam@gmail.com

INTRODUCTION:

Candidiasis is a superficial skin or mucosal infection caused by a yeast-like fungus, *Candida albicans*^[1], a popular commensal organism that commonly colonizes the oral mucosa and is readily isolated from the oral cavities of the healthy individuals.^[6] The organism has a predilection for warm, moist environments^[2] and is responsible for about 95% cases of oral candidiasis(OC).^[3-5] Acute

Pseudomembranous Candidiasis (APC), often referred to as “thrush”, is the most commonly diagnosed and most easily recognizable form of OC, accounting for a third of cases. ^[7] It causes opportunistic infection since the escalation in acquired immuno-deficiency syndrome (AIDS) and till date it remains the most common oral infections amongst the immuno-compromised subjects. It encompasses

infections of the tongue and other oral mucosal sites and is characterized by fungal overgrowth and invasion of superficial tissues which may lead to local discomfort and may deter normal eating habits. [7-9]

The oral carriage of *Candida albicans* is reported to be 30-45% in the general healthy adult population. [10] The most prevalent protein secreted by *Candida albicans* is secreted aspartyl proteinase (SAP), which has the ability to break down a variety of human proteins, including mucin, extracellular matrix proteins, immune-system molecules, endothelial cell proteins, coagulation and clotting factors, salivary lactoferrin, and others. This significantly increases *Candida albicans*' ability to cause disease. [11] It is frequently seen to affect children and the elderly population, equally affecting both males and females. It can occur when a patient's immunity gets disrupted which can be due to local causes, secondary to use of oral steroids, and antibiotics, ill-fitting dentures, nutritional deficiencies, high carb diet, malignancies, poor oral hygiene and heavy smoking habits which reduces polymorphonuclear leukocyte function and allows *Candida* overgrowth & colonization eventually leading to the formation of a pseudo membrane. [12]

The following features are observed in cases of APC- [1,10]-

1. It is mainly seen to affect those of extremes of age (infants and old people) and the vast majority of cases are seen among smokers and due to use of steroids or those living on high carb diet.
2. It usually presents as a multi-focal, curdy yellow white plaques, throughout the oral mucosa, mainly over the buccal mucosa, tongue, soft palate and sometimes down the oesophagus [1].

3. The white patches can be easily removed with gauze, leaving an erythematous mucosal surface.
4. The pseudo membrane, thus formed, consists of fibrin, desquamated epithelial cells, fungal hyphae and sometimes bacteria or food debris.
5. The infection can often be asymptomatic and other times the patient will describe discomfort such as burning sensation, occasional bleeding, tenderness or changes in taste, when large part of mucosa is involved.
6. Dysphagia

The diagnosis is essentially a clinical one based on the presence of distinctive clinical features [8]- and can be confirmed by microscopy and culture of skin swabs. [2] A detailed clinical examination, past medical history and assessment of risk factors may help us diagnose the case properly. Cultures and sensitivity tests can further be done if anti-fungal treatment is ineffective. [1,10] If left untreated, there are high chances of recurrence which can subsequently progress to oesophageal candidiasis leading to difficulties in swallowing and nutrition. [6] With the use of pharmaceuticals like broad-spectrum antibiotics and immunosuppressive drugs in recent years, the aetiology of oral candidiasis has changed, and an increase in drug-resistant candidiasis has been reported. They have become inherently resistant to antifungal medications and have become more severe and challenging to cure. [13] Here, Visual Analog Scale (VAS) is used to evaluate the improvement of candidiasis. It is based on numerical scoring of the symptoms between 0 to 10 that best describes the intensity of the suffering. 0 means "no pain" whereas 10 means "worst possible pain." More severe symptoms are indicated by higher ratings. Homoeopathic treatment goes beyond treating the bodily symptoms and takes a

more all-encompassing approach. Homoeopathy views the expression of illness in one portion in relation to the entire man rather than considering any one part to be ill. Homoeopathic treatment is focused on taking into account all of the symptoms experienced by a patient. A case report of a patient suffering from APC, who was successfully treated with individualized Homoeopathic medicine, is presented in this article.

CASE REPORT:

A 72-year old, male non-diabetic, non-hypertensive patient, attended the outpatient department on 03.04.2023, with chief complaints of thick yellow white coating on the tongue and patchy white deposits in the buccal mucosa that has been persisting since the last three weeks. There was burning pain whenever he ate or drank anything or even slightest touch. The patient gave history of having consumed a sweetmeat after dinner three days ago. The following morning when he brushed his teeth and tried to use a tongue cleaner, the layer came off leaving behind raw, ulcerated surface. On further enquiry, it was learnt that he has been a chronic smoker and also reported of having been suffering from oral dryness from the past three months which is distressing for the patient as it flares up especially after taking anything sweet, slimy or spicy. He had consulted a dentist, an ENT and a general practitioner for the same. He

1. Fastidious.
2. Irritable
3. Chilly patient
4. Desire for highly seasoned foods
5. Desire for sweets
6. H/O- Smoking
7. Sleeplessness

With the help of characteristics mental and physical symptoms above, a totality was formed, thus individualizing the patient.

was prescribed anti-fungals for the same, but it didn't offer him any substantial relief, instead aggravated and spread more to other sides in the subsequent episodes. Past medical history supported of having gastric ulcer 18years ago which was cured and never recurred. He also complained of having similar episodes of oral thrush since the last three months. He is a retired gentleman of high intellect, fastidious and anxious, who spends most of his time at home. Among generals, he had an irregular diet plan with special craving for sweets, tea and spicy non-vegetarian items. He has moderate thirst and bowel movements are regular on first waking. He had complaints of having a disturbed sleep cycle. He has tendency to catch cold easily with frequent bouts of sneezing when exposed to cold air in the morning. He is a chilly patient and always wants to be wrapped. The patient was anxious and irritable due to his complaints.

On clinical examination- diffuse, yellowish-white curdy plaques were seen, coating the tongue thick posteriorly with deep ulcerations in the centre and on the outer margins (Fig-1). These plaques were painful on scraping and showed erythematous mucosa. The above findings supported the straight forward clinical diagnosis of acute pseudomembranous candidiasis.

Totality of symptoms-

8. Intolerance to cold air, causes sneezing.
9. Tendency to take cold
10. Tongue coated yellow-white posteriorly
11. Burning pain and dryness of tongue
12. Sedentary lifestyle.

Taking into considerations his symptoms and the miasmatic background, the patient was prescribed *Nux vomica 200/ 2 doses* followed by placebo along with some non-

medicinal management and maintenance of good oral hygiene. He was also assessed on VAS score at the end of each month to know the improvement status and Quality of life(QoL). The patient at first showed a gradual progress followed by a smooth and quick improvement as the white plaques

started clearing off and the coating started to fade off. His VAS scores showed remarkable improvement from **9** to **0** at a span of 3 months. When he followed-up next he was much better and gradually the normal texture of the tongue was restored without any recurrence.

Table-1: Therapeutic intervention and Timeline

Date	Present Complaints	Prescribed Medicines
First visit 03.04.2023	Complaints of thick yellow white coating on the tongue and patchy white deposits in the buccal mucosa, with deep ulcerations in the centre and on the outer margins that has been persisting since the last three days. There was burning pain whenever he ate or drank anything or even slightest touch	<i>Nux vomica 200/ 2 doses</i> followed by placebo for 2 weeks VAS score-9
Second visit 17.04.2023	The thick coating slightly faded off with healing of pain intensity of the ulcerations. The patient reported of lessening in the intensity of the burning pain of the tongue.	Placebo twice a day for another one month VAS score-6
Third visit 22.05.2023	The coating and ulcerations have faded considerably. The white plaques have faded in intensity. Burning pain is much less.	Placebo for another one month, once a day. VAS score-3
Fourth visit 19.06. 2023	The coating and ulcerations are no more seen. The white plaques have cleared off and normal texture of the tongue is restored. Burning pain occasionally seen.	Placebo for another one month, once a day. VAS score-1
Fifth visit 10.07.2023	The normal texture of the tongue is restored. Burning pain not reported all this while. The patient did not complain of further recurrence of the complaints. VAS score-0	

Clinical images & progress:

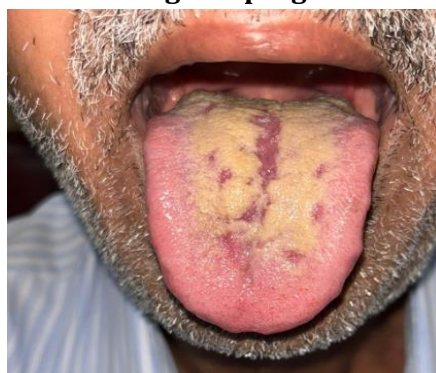

Fig 1: 1st visit (03.04.2023)

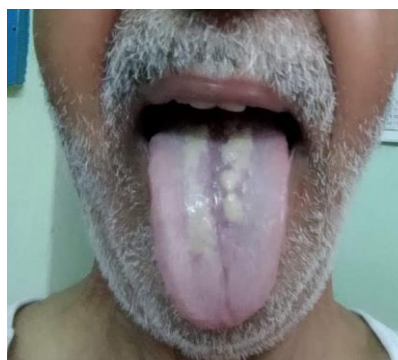

Fig 2: 2nd visit (17.04.2023)

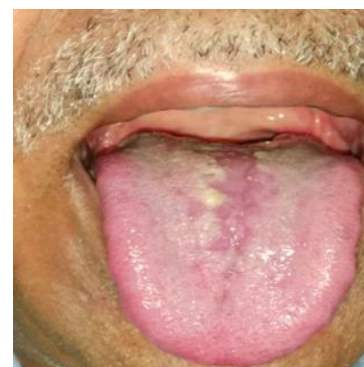

Fig 3: 3rd visit (22.05.2023)

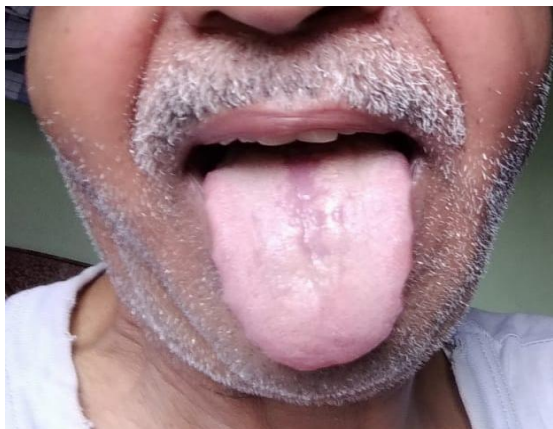

Fig 4: 4th visit (19.06. 2023)

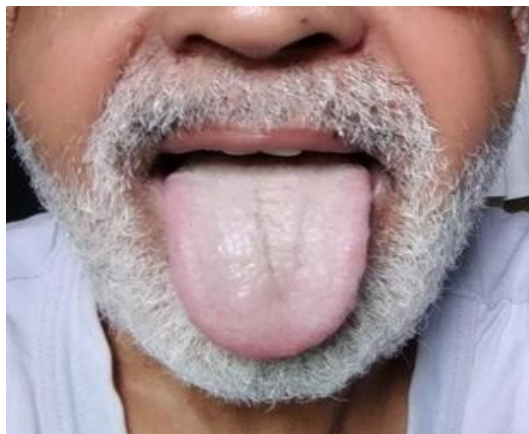

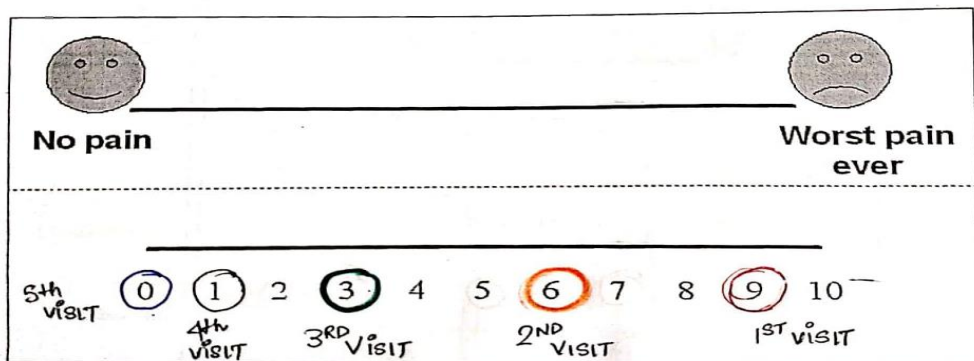
Fig 5: 5th visit (10.07.2023)

APPENDIX-4

Visual Analogue Scale (VAS)

OPTION 2

- Print or photocopy the next 2 diagrams on an A4 sheet ensuring that the lines are exactly 10 cm in length
- Fold at the dotted line
- Do not show the patient the numbered scale



Numerical rating scale (NRS)

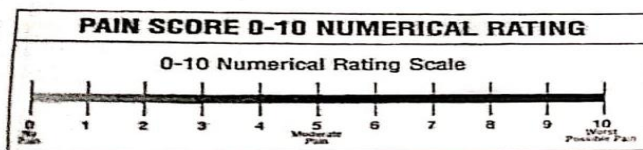


Fig.6- Changes in the VAS scores at different times of follow-up.

DISCUSSION-

Acute pseudomembranous candidiasis is one of the most common fungal infection seen maximally of about 60% among patients over the age of 60 years. [14] APC presents clinically as yellow white curdy

patches over the oral mucosa especially over the tongue, buccal mucosa and at times spread to the oro-pharynx. It is often diagnosed clinically and needs prompt treatment to avoid further complications. The incidence of salivary oral dryness is increasingly seen among the ageing

population and rampant use of steroids, tobacco and antibiotics. Tobacco cigarette users are known to have significantly increased risk of developing APC as it was suggested that cigarette smoking may cause a decrease in salivary immunoglobulin A (IgA) and a depression of neutrophil function encouraging oral colonization of *Candida*. It is also theorized that smoking cigarettes can provide nutrition for *Candida* to produce carcinogens.

The above case of this old gentleman, smoker and leading a sedentary lifestyle who had been suffering from oral dryness which gradually led to the development of candidiasis of acute pseudomembranous variety is a common incidence before us but is often neglected at the hands of the conventional treatment, missing out on the effects of ultra-dynamized Homoeopathic medicines. It is seen from the present case that individualized homeopathic medicine, *Nux vomica* yielded good results in APC. The drug contains *strychnine*, as its active principle, which is known to have an inhibitory effect on the proliferation of micro-organisms like *Candida albicans*.^[15] Thus, studying Homoeopathic drugs by knowing their active principles and its therapeutic effects on various clinical conditions apart from the symptoms noted in the words of proverbs can provide us an insight to a scientific learning and a satisfactory prescription while treating patients. Hence, Homoeopathy can safely, smoothly cure a patient in a non-invasive, pocket-friendly way without any adverse outcomes. This case intended to highlight the evidence based learning as well as treating of such common cases that we come across frequently with the help of Homoeopathic medicines.

CONCLUSION:

This case report intended to highlight the positive effect of Homoeopathic medicine *Nux vomica* in a case of acute pseudomembranous candidiasis based on individualization, suggesting the need to further research on its active principles and their role on fungal infections. The other factors supporting the progress of disease like high-carb diet and smoking needs to be checked into as it hampers the protective function of saliva and thus favours the fungal growth.

Limitations of the study:

This is a single case report. In future, case series can be recorded studying the effects of different drugs on APC with an individual approach focusing on the active principles and their therapeutic roles in such clinical cases.

Declaration of the patient's consent:

The authors certify that they have obtained all appropriate patient consent for treatment and publication of images without disclosing the identity of the patient.

REFERENCES:

1. Khanna N. Fungal Infections. In: Illustrated synopsis of dermatology & sexually transmitted diseases. 5th ed. New Delhi: Elsevier India; 2019. p. 312-5.
2. Penman ID, Ralston S, J. SMW, Hobson RP, Ibbotson SH. Dermatology. In: Davidson's principles and practice of medicine. 24th ed. London: Elsevier; 2023. p. 1093.
3. Williams, D.; Lewis, M. Pathogenesis and treatment of oral candidosis. J. Oral Microbiol. 2011, 3. s
4. Naglik, J.R.; Moyes, D.L.; Waächtler, B.; Hube, B. *Candida albicans* interactions with epithelial cells and mucosal

- immunity. *Microbes Infect.* 2011, 13, 963–976.
5. Southern, P.; Horbul, J.; Maher, D.; Davis, D.A.C. *albicans* colonization of human mucosal surfaces. *PLoS ONE* 2008, 3, e2067.
 6. Vila T, Sultan AS, Montelongo-Jauregui D, Jabra-Rizk MA. Oral Candidiasis: A Disease of Opportunity. *Journal of Fungi.* 2020; 6(1):15.
 7. Millsop JW, Fazel N. Oral candidiasis. *Clin Dermatol.* 2016;34(4):487-94.
 8. Singh, A.; Verma, R.; Murari, A.; Agrawal, A. Oral candidiasis: An overview. *J. Oral Maxillofac. Pathol.* 2014, 18, S81–S85.
 9. Hellstein, J.W.; Marek, C.L. Candidiasis: Red and white manifestations in the oral cavity. *Head Neck Pathol.* 2019, 13, 25–32.
 10. Akpan, A., and Morgan, R. (2002). Oral candidiasis. *Postgrad. Med. J.* 78, 455–459.
 11. Gupta SR, Xess I, Singh G, Sharma A, Gupta N, Sharma S, et al. Therapeutic implications of candida phenotypes, virulence factors and antifungal sensitivity in Oral leukoplakia. *J Oral Biol Craniofac Res.* 2021;11(2):354–60.
 12. Taylor M, Brizuela M, Raja A. Oral Candidiasis. [Updated 2023 Mar 19]. In: StatPearls [Internet]. Treasure Island (FL): StatPearls Publishing; 2023 Jan-. Available from: <https://www.ncbi.nlm.nih.gov/books/NBK545282/>
 13. Hato H, Sakata K, Sato J, Hasebe A, Yamazaki Y, Kitagawa Y. Factor associated with oral candidiasis caused by co-infection of candida albicans and candida glabrata: A retrospective study. *Journal of Dental Sciences.* 2022;17(3):1458–61.
 14. Mallya, Sachidananda and Mallya, Shrikara (2019) 'Candida and oral candidosis—a review', *Journal of Health and Allied Sciences NU*, 09(02), pp. 39–44..
 15. Mohesh, Glad & Joy, A & Ratchagan, K & Sundaramurthy, A. (2015). Antibacterial and antioxidant activity of *Strychnos nux vomica* flower extract. *Journal of Chemical and Pharmaceutical Research.* 2015. 748-752.

Conflict of interest: Author declares that there is no conflict of interest.

Guarantor: Corresponding author is guarantor of this article and its contents.

Source of support: None

How to cite this article:

Khanam H, Halder S. Acute Pseudomembranous Candidiasis is treated Successfully with Homoeopathy- An Evidence Based Homoeopathic Case Report. *Int. J. AYUSH CaRe.* 2023;7(3):320-326.