

Management of *Mutrashmari* (Urolithiasis) with Ayurvedic Formulations - A Case Report

Monika Kumari,^{1*} Deepak AS,¹ Kalanidhi Hota,¹ Vyasadeva Mahanta,² Yogesh Badwe³

¹PhD Scholar, ²Associate Professor, ³Professor and HOD, Department of Shalya Tantra, All India Institute of Ayurveda, New Delhi, India.

ABSTRACT:

Mutrashmari co-related with Urolithiasis is considered as one of the *Ashta-Mahagadas* (Eight Dreadful diseases) due to its incurable nature and is contemplated as *Yama* because it gives intolerable pain. Stone of small size can be easily treated conservatively with Ayurvedic formulations. In this study, a 21-year-old male patient presented with bilateral flank pain, nausea, and dysuria persisting for two months. Ultrasonography revealed a 7 mm calculus in the left kidney at the mid pole, a 3 mm calculus in the right mid ureter, and concretions in all kidney calyces, as confirmed by NCCT (KUB) imaging. The patient experienced substantial symptom relief through the administration of Ayurvedic formulations, namely *Pashanbhedadi kwatha churna* 5g twice daily, *Chandraprabha Vati* 500 mg twice daily, and *Gokshuradi Guggulu vati* 500 mg twice daily throughout the treatment period of 3 months. Compliance with dietary recommendations also contributed to the patient's improvement. Subsequent ultrasonography revealed normal findings. Following three months of treatment, the renal calculus was successfully removed, leading to the alleviation of symptoms.

KEYWORDS: *Chandraprabha Vati*, *Gokshuradi Guggulu*, NCCT, *Pashanbhedadi churna*, USG, Urolithiasis.

Received: 19.02.2024 Revised: 17.03.2024 Accepted: 19.03.2024 Published: 20.03.2024



[Creative Commons Attribution-NonCommercial-No Derivatives 4.0 International License](https://creativecommons.org/licenses/by-nc-nd/4.0/)

© 2024 International Journal of AYUSH Case Reports | Published by Tanaya Publication, Jamnagar.

Quick Response Code



*Corresponding Author:

Dr. Monika Kumari

PhD Scholar,

Department of Shalya Tantra, All India Institute of Ayurveda, New Delhi, India.

E-mail: dr.monika19@rediffmail.com

INTRODUCTION:

Ashmari (~Urolithiasis) comprises of two words 'Ashma' and 'Ari'. *Ashma* means a stone and *Ari* means enemy. *Ashmari* (Urolithiasis) is a disease in which there is formation of stone, resulting into severe pain as given by enemy. *Ashmari* (~Urolithiasis) in *Ayurveda*, is one among the *Ashtomahagada* (~Eight dreadful diseases).^[1] Its etiology, believed to originate from the *basti* (~bladder), a significant area among *dasavidha pranayatana* (~tenfold vital centers), adds to its complexity in treatment. The severe pain accompanying this condition has resulted in its likening to *Yama*, the deity symbolizing death.^[2] *Acharya Sushruta*, in his description of the symptoms of *Ashmari* (~Urolithiasis), discusses the location, nature, intensity, and factors exacerbating and alleviating pain, resembling the symptoms of ureteric colic in modern medicine.

It affects around 12% of the world population and the increased frequency is mainly attributed to high standards of living and is strongly associated with race and region of residence. According to epidemiological data, prevalence of urolithiasis in adult ranges from 1-20% with great incidence noted between ages 20-40 years.^[3] Urolithiasis occurs when crystals that the stone is composed of supersaturate the urine due to being present in a high concentration and begin to collect and crystallize within the parenchyma of the kidney, forming the renal calculi. These crystals will aggregate together and continue to enlarge with the potential to migrate into the ureter and become symptomatic. If the stone causes an obstruction and does not allow for the passage of urine through the ureter, hydronephrosis can occur secondary to upstream dilation of the ureter and renal pelvis.^[4] Stones are painful within the ureter

because as they pass through the ureter, increased luminal tension and hydronephrosis will lead to prostaglandin release, resulting in colicky pain associated with the condition.

Urolithiasis is a lifestyle disease. Sex, age, race, place of residence (geographical region), chronic diseases, lifestyle (including diet) and various genetic factors contribute to the risk of calculus formation within the urinary tract.

The treatment of urolithiasis is based upon the patient's acute presentation and includes both conservative medical therapies and surgical interventions. Often when patients present, pain control is an important intervention. Oral and IV anti-inflammatory medications (NSAIDs) are indicated as first-line treatments for pain. Opioids can be used but are reserved for refractory pain. IV lidocaine has also been studied as an effective pain control option.^[5] Nausea and vomiting should be treated with IV antiemetic medications.

Most patients presenting with urolithiasis have an excellent prognosis. Asymptomatic/calyceal stones (non-struvite) typically do not require acute intervention and can be monitored over time with a routine evaluation with ultrasound or KUB.

CASE HISTORY:

A 21-year-old normotensive and non-diabetic male patient presented with complaints of B/L flank pain of on & off nature, nausea and burning micturition occasionally since last 2 months for which he consulted to local doctor who gave him analgesics and antacids and with that he was advised to undergo USG (whole abdomen). In the USG (02/04/2023) it was confirmed that the patient was having a stone of size 7 mm in left kidney at mid pole and a stone of size 3 mm in right mid ureter. On second visit to the doctor, he was advised surgery for same but patient wants to have second opinion for which he came to Shalya OPD of AIIA. A new USG (KUB) as well as NCCT (KUB) was done for the diagnostic evaluation in which the above mentioned size of stones and additional concretions were also seen in all the calyces of Right kidney

According to the symptoms the STONE Score [6] was assessed and was found to be moderate. There was no history of Diabetes mellites or Hypertension. Diet history revealed that his food intake was irregular in terms of quality and quantity due to his stressful occupation.

All general examinations and vitals were within normal limits. On examination of the abdomen, there was no organomegaly but

tenderness elicited in both sides of the lumbar region and left side of the renal angle.

Investigations:

Ultrasonography of the whole abdomen region (02-04-2023) revealed calculus of size 7mm measuring in the left kidney, without any evidence of hydronephrosis and 3 mm calculus in the right mid ureter. Finally it was confirmed that it was Urolithiasis.

NCCT KUB report shows calculus of size 7.5 mm (CT value = 1600 HU) in the mid pole of left kidney and 3.4 mm calculus in the right mid ureter of CT value 600 HU and hyperdense concretions were seen in all calyces of right kidney largest size was measuring 1-1.5 mm having CT value 400 HU.. His blood and urine reports were within normal limits. **(Table 1a and 1b)**

THERAPEUTIC INTERVENTIONS:

Pashanbhedadi churna [7] 5g BD before food twice daily

Chandraprabha vati [8] 500mg BD with luke warm water after food

Gokshuradi Guggulu [9] 500 mg BD with luke warm water after food

Along with *Ayurvedic* formulations the patient was also provided with a *Pathya apanya* chart and was advised to take plenty of fluids (> 2 litres of water) and *Kulaththa Yusha* (50 ml) thrice daily. **(Table 2)**

Table 1 (a) : Blood Report:

Hb%	13.5 g/dl	RBS	105 mg/dl	Na+	138 meq/L
TLC	8000/mm ³	Bl Urea	28 mg/dl	K+	3.8 meq/L
DLC	N ₅₄ L ₃₆ M ₅ L ₅ B ₀	Sr Creatinine	1.0	Cl	105.4 meq/L
Platelet Count	2,50,000 /mm ³	Sr calcium			

Hb%= Haemoglobin

TLC = Total Leucocyte Count

DLC = Differential Leucocyte Count

Sr Calcium = Serum Calcium

K = Serum Potassium

RBS = Random Blood Sugar

Bl Urea= Blood Urea

Sr Creatinine = Serum Creatinine

Na = Serum Sodium

Cl = Serum Chloride

Table 1b: Urine test report

Urine (R&M)			
Volume	20ml	Glucose	Nil
Colour	Pale Yellow	Epithelial cells	Nil
Appearance	Clear	Pus cells	Nil
pH/reaction	6.5	Erythrocytes	0-1
Specific gravity	1.019	Cast	Nil
Albumin	Nil	Crystals	Nil
Urine C&S :	No growth was seen after 48 hrs of incubation		

Table 2: Prescribed Ayurvedic Formulations:

Interventions	Dose	Form	Dosage	Time
<i>Pashanbhedadi Churna</i>	5g	Kwatha	Twice daily	Before food with plain water
<i>Chandraprabha Vati</i>	500 mg	Vati	Twice daily	After food with plain water
<i>Gokshuradi Guggulu</i>	500 mg	Vati	Twice daily	After food with warm water

Table 3: Details of Follow up

Date and follow up	Pain (VAS Score)	Burning Micturition	Nausea
21/4/23	Pain in B/L flank (VAS = 6)	Burning Micturition (Mild ; on and off)	Nausea (on and off)
1 st follow up (after 15 days) 6/4/23	Mild Pain in B/L flank region (VAS=2)	No complaint of Burning Micturition	No complain of Nausea
2 nd follow up (30 th day) 21/5/23	Pain in Right flank (VAS=5)	Mild burning in micturition	Nausea
3 rd follow up (1and half months) 5/6/23	Mild Pain in Left flank	No complaint of Burning Micturition	No complain of Nausea
4 th follow up (2 nd month) 20/6/23	No complain of Pain in flank	No complaint of Burning Micturition	No complain of Nausea
5 th follow up (2 and half months) 5/7/23	Mild pain in Left Flank	No complaint of Burning Micturition	No complain of Nausea
6 th follow up (3 rd months) 20/7/23	No complain of Flank	No complaint of Burning Micturition	No complain of Nausea

Table 4: USG and NCCT Details of follow up:

Date	USG and NCCT findings
2/4/23	USG (KUB)=7.3 in the middle calyx of left kidney and 3.4 mm in the mid ureter of right side(Figure 1)
20/4/23	7 mm in the middle calyx of left kidney and 3 mm in the mid ureter of right side 21/4/23 NCCT (KUB)= 7.5 mm (CT Value=1600 HU) at the left middle calyx, 3.4 mm (CT Value= 600HU) in the right mid ureter and concretions in all the calyces largest measuring 1-1.5 mm (CT Value=400 HU) in the Right kidney. (Figure 5)
22/5/23	USG (KUB)=6 mm in the middle calyx of left kidney (Figure 2) 23/5/23 NCCT (KUB) = 6 mm (CT Value=1400 HU) in the left middle calyx and co at lower calyx (CT Value=300 HU) of right kidney (Figure 6)
26/6/23	USG (KUB)=3 mm in the middle calyx of left kidney (Figure 3) NCCT (KUB) 26/6/23= 4.8 mm (CT Value=1000 HU) in the middle calyx of left kidney (Figure 7)
28/7/23	USG (KUB)= Normal Study (Figure 4)
2/8/23	NCCT (KUB) = Normal Study (Figure 8)

Investigations reports

Taravati Ram Gopal
MEHRA FOUNDATION
 CLINICAL LAB (FULL COMPUTERISED)
 300 MA.A DIGITAL X-RAY
 E.C.G. *ULTRASOUND*CT SCAN
 Plot No. 8, I.P. Extension, Palapgarj,
 Near 'Navnil' Apartments, Delhi-110092
 Phone : 22247005, 22246489

NAME: MIRAMAN AGE: 20Yrs/M Dated:- 02.04.2023

Ultrasound Examination of Whole Abdomen:

Liver: Liver is normal in size, shape & shows normal parenchymal echotexture. No focal SOL is seen in liver. IHR & portal radicles are normal. Portal vein is normal in course & caliber.

Gallbladder: Gallbladder is well distended with normal anechoic lumen. GB wall is normal. There is no evidence of any mass or gall stone. Common bile duct is normal in course & caliber.

Pancreas: Pancreas shows normal size & echotexture. No focal SOL is seen. Pancreatic duct is normal.

Spleen: Spleen is normal in size, shape & shows normal outline & echotexture.

Kidneys: Kidneys show normal size, shape, position & echotexture. Cortico-medullary differentiation and cortical thickness is normal on both sides. No SOL is seen in both the kidneys. There is no hydronephrosis or hydroureter on both sides. No supra-renal mass seen. A calculus of size 7.3 mm is seen in left kidney and 3.4 mm calculus is seen in right mid ureter.

Urinary bladder: Urinary bladder shows normal anechoic pattern. No calculus, SOL or diverticulum seen.

Prostate: Prostate and seminal vesicles are normal.

Great abdominal vessels are normal. No axillary or retroperitoneal lymph nodes noted.

Please correlate clinically.

Dr. Rakhee Chatterjee
 MBBS, MD, Radio-Diagnosis
 (Consultant Radiologist) DMC: 63468

All India Institute of Ayurveda
अखिल भारतीय आयुर्वेद संस्थान
 आयुर्वेद मंत्रालय, भारत सरकार के अंतर्गत स्वायत्त संस्थान
 (An Autonomous Organization under the Minister of AYUSH, Govt. of India)

UHD No. : 158826 Receipt No : Paid
 Patient Name : Miraman IPD No :
 Age / Sex : 21 Years / M Panel : Credit
 Consultant : Dr. Prashant Date : 22/05/2023

Usg Kub Report

Both kidneys are normal in shape, size and echotexture without evidence of any focal defect, hydronephrosis and mass lesion. The renal parenchymal thickness and echogenicity is normal on bilateral side. CM differentiation is well maintained on both sides.

The right kidney measures 9.6 cm in length.
 The left kidney measures 9.8 cm in length shows a calculus of 6 mm in the middle calyx.

The urinary bladder is normal in appearance.
 The prostate is normal in shape and size seen on per abdominal examination.

Both the seminal vesicles are normal in appearance.

IMPRESSION:
Left non-obstructive renal calculus.

Advise: Clinical correlation.

Dr. Prashant Yadav
 MBBS, MD (Radiology)
 Consultant radiologist

Figure-1: US findings before treatment

Figure-2: USG findings 2nd follow up

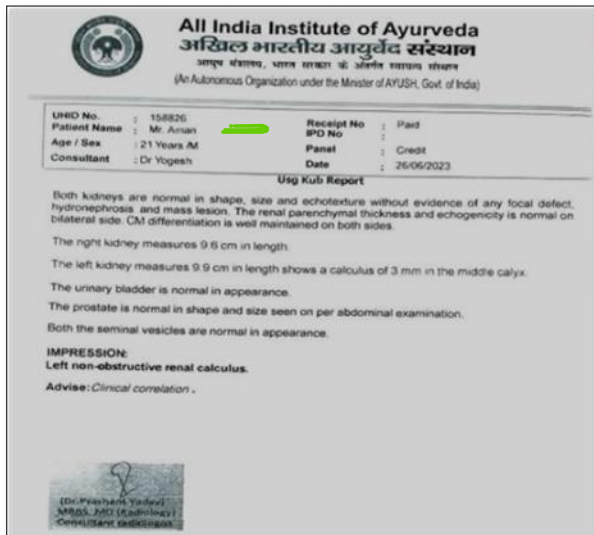


Figure-3: USG report 4th follow up

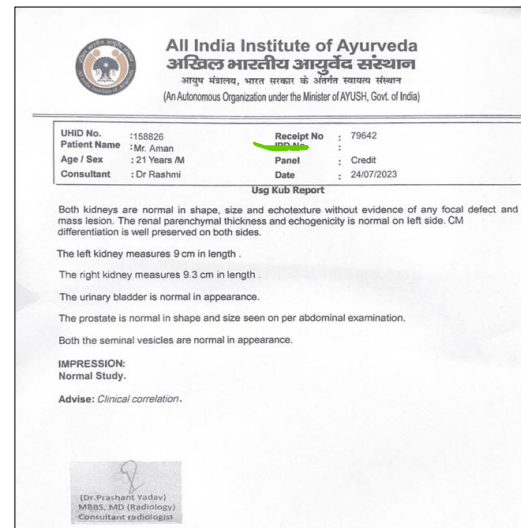


Figure-4: USG Report After treatment

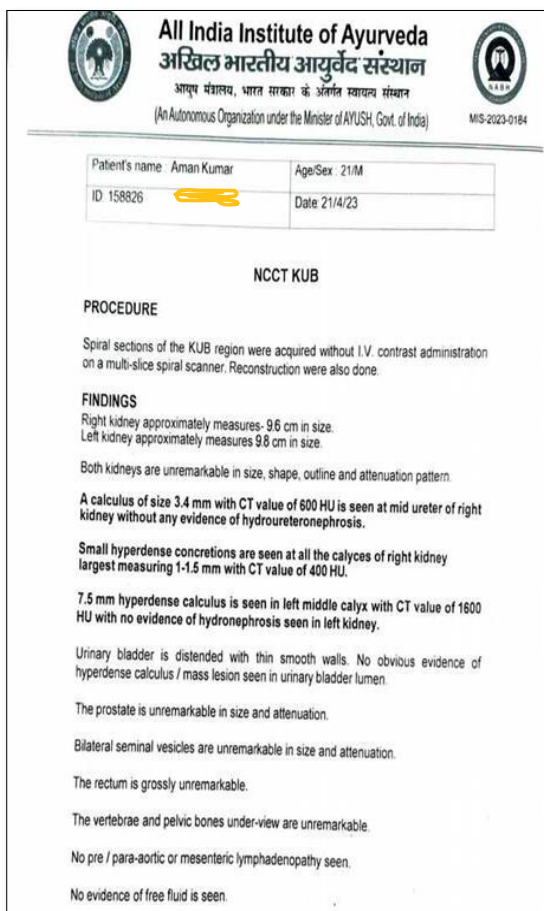


Figure-5: NCCT KUB report before treatment

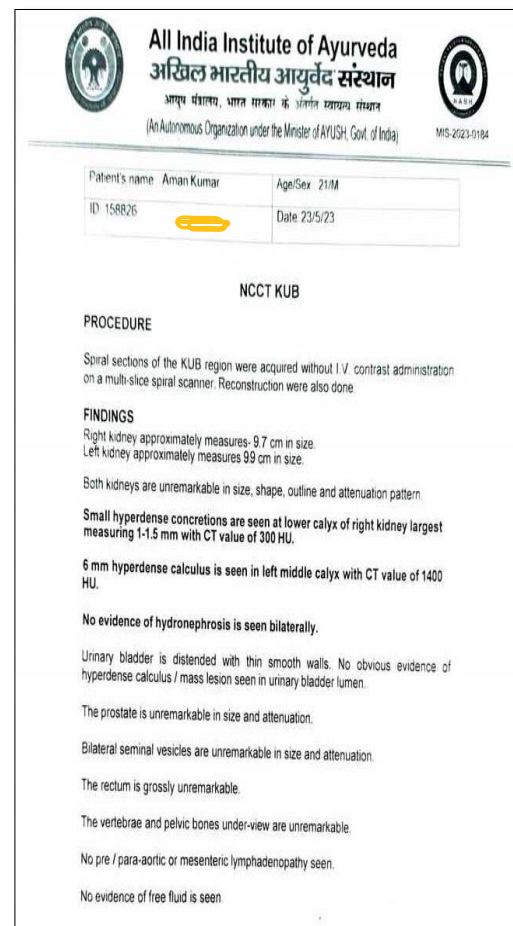


Figure-6: NCCT report 2nd follow up

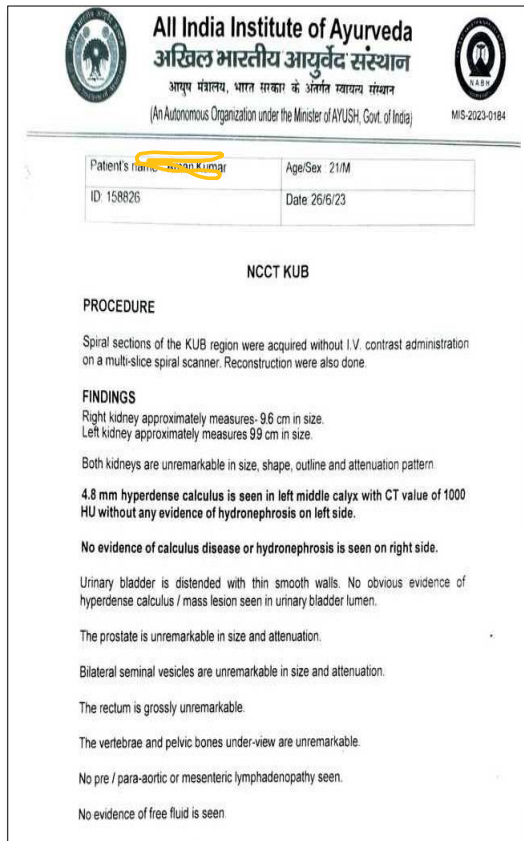


Figure-7: NCCT report on 4th follow up

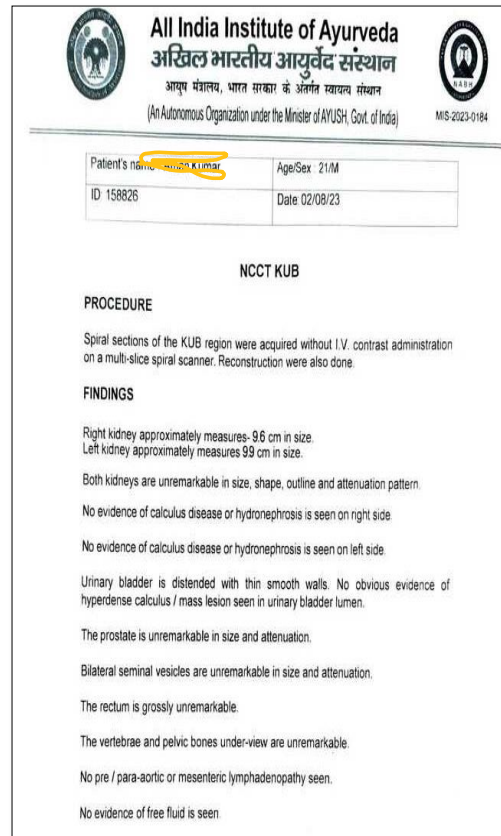


Figure-8: NCCT report after treatment

Follow up and outcome:

During his 1st follow-up, it was noticed that all clinical features were absent except for mild pain in abdomen. He was advised to repeat Ultrasonography of abdomen and pelvis on 20-05-2023. Report reveals, a single calculus measuring 6 mm in the lower calyx of right kidney. (Figure- 1)

On the second follow up, patient again complains of pain in the right flank region, mild burning and nausea for which USG was advised. USG reports revealed that the stone present in left kidney was reduced in size and the stone present in right mid ureter was expelled out. (Figure- 2)

He was asked to continue all internal medications along with *Pathyapathya* (Do's & Dont's) and was advised next (3rd) follow-up after 15 days. This time the patient was having only complaint of pain in left flank region other symptoms got subsided.

On 4th follow up, (Figure-3) patient symptoms subsided significantly and again a USG (KUB) was advised in which the stone size was reduced and he was advised to continue same medication for around 1 month (5th follow up) After a month (in 6th follow up) (Figure- 4) patient was completely relieved from and has experienced neither burning micturition nor nausea till date. This time scan report confirmed that, there is no absolute calculus in the urinary tract. This shows that there was no evidence of calculus in the urinary tract.

DISCUSSION

Ashmari (~Urolithiasis) as described comes under one of the dreadful disease mentioned in *Ayurveda*. Being correlated with Urolithiasis in modern science, shows pain of colicky nature if the stone is present in ureteric region along with complaints of

burning micturition, nausea/vomiting, fever, haematuria, dysuria etc. These stone is easily diagnosed by the clinical features and with the investigations such as USG (either whole abdomen / KUB) and Non-contrast computed tomography (NCCT).

For the treatment of *Mutrashmari* (~Urolithiasis) many formulations have been mentioned in *Ayurveda* by *Acharyas* which not only has shown promising result in reduction in number, size of stone but also reduces the symptoms as presented in cases of *Mutrashmari* (~Urolithiasis). The drugs used mainly in this case report is *Pashanbhedadi churna*, *Chandraprabha vati* and *Gokshuradi guggulu* along with *Pathya-apathya abara* and intake of plenty of fluids and *Kulattha Yusha* (around 15 ml per day thrice daily)

Mode of action of *Pashanbhedadi Churna*:

Pashanbhedadi ^[10] is a commercially available diuretic and lithotropic drug and have anti-inflammatory, antilithic, antiviral, anti-bradykinin, antibacterial, Liver protective, antipyretic activity etc. ^[11]

Mode of action of *Chandraprabha vati*:

Chandraprabha vati is a multifaced drug and can be used in a variety of ailments successfully. It acts as *mutrala*, *Deepana pachana*, *rasayana*, *tridoshagna*, anti-inflammatory, antidiabetic etc. ^[12]

Mode of action of *Gokshuradi Guggulu*:

Gokshuradi guggulu have lithotriptic, diuretic, antispasmodic, antioxidant ^[13], anti-inflammatory ^[14], antiseptic activities. One of the herbs present in *Gokshuradi guggulu*, *musta*, might help stimulate the expulsion of the stone in the urine.

CONCLUSION

As this is single case study, the same intervention can be used on larger population to see the efficacy of *Pashanbhedadi Churna*, *Chandraprabha vati* and *Gokshuradi Guggulu* alongwith *Kulattha Yusha* and *Pathya* in the management of *Mutrashmari* (~Urolithiasis). To decrease the risk of further stone formation, a patient is strictly advised to follow certain rules of conduct, diet and lifestyle regime (*Pathyapathya*) during the course of *Ayurvedic* treatment and thereafter to prevent reoccurrence.

Patient consent:

A proper informed consent about the given treatment was taken from the patient before undergoing the treatment.

Conflict of interest: Author declares that there is no conflict of interest.

Guarantor: Corresponding author is guarantor of this article and its contents.

Source of support: None

How to cite this article:

Monika Ku, Deepak AS, Hota K, Mahanta V, Badwe Y. Management of *Mutrashmari* (Urolithiasis) with *Ayurvedic* Formulations -A Case Report. Int. J. AYUSH CaRe. 2024;8(1): 53-61.

REFERENCES:

1. Dalhanacharya, Nibandha Sangraha, Sushruta samhitha of Sushruta, Vaidya Yadavji Trikamji Acharya, Nidanasthana; Ashmari nidana dyaya: Chapter 3, Verse 3, 4, 5. Choukhambha Samskrita Samsthana, Varanasi. 6 th Edition (reprinted), 1997; p.276-280
2. Sushruta, Sushruta Samhita Nibandha Sangraha Sushruta Sutra Sthana 33/4-

- 5, Chaukhamba Orientalia, Varanasi 2007., P-144, & 824.
3. Trinchieri A: Epidemiology of urolithiasis: An update Clin cases Kliner Bone Metab 2008;5:101-106
4. Thakore P, Liang TH. Urolithiasis. [Updated 2023 Jun 5]. In: StatPearls [Internet]. Treasure Island (FL): StatPearls Publishing; 2023 Jan-. Available from: <https://www.ncbi.nlm.nih.gov/books/NBK559101>
5. Gottlieb M, Long B, Koyfman A. The evaluation and management of urolithiasis in the ED: A review of the literature. Am J Emerg Med. 2018;36(4):699-706
6. Wilson R. Molina, Fernando J. Kim et al ;The S.T.O.N.E. Score: A new assessment tool to predict stone free rates in ureteroscopy from pre-operative radiological features Int. Braz J Urol. 2014;40 (1):20-25.
7. Ravidatta Tripathi. Charaka Samhita Vol. II (Chikitsa Sthana) chapter 26, verse 60-61, Delhi: Chaukhambha Sanskrit Pratishthan; 2013. p.634
8. Shastri P, editor. Sarangdhar Samhita of Sarangdhar, Madhyama khanada Chap 7, verse 40-47, Chaukhamba Surbharti Prakashan, Varanasi. 2013
9. Shastri P, Sarangdhar Samhita of Sarangdhar, Madhyama khanada Chap 7, verse 84-87, Chaukhamba Surbharti Prakashan, Varanasi. 2013 p-14
10. [https://www.netmeds.com/health-library/post/Pashanbhed: Uses, Health Benefits, Ayurvedic Indications, Dosage, Side Effects And Precautions \[Revised on date June 22,2022\]](https://www.netmeds.com/health-library/post/Pashanbhed: Uses, Health Benefits, Ayurvedic Indications, Dosage, Side Effects And Precautions [Revised on date June 22,2022])
11. <https://www.netmeds.com/>; Pashanbhed: Uses, Health Benefits, Ayurvedic Indications, Dosage, Side Effects and Precautions, [Lats accessed June 22, 2022].
12. Preetimayee Sahoo Nihar Ranjan Mahanta; A Critical Analysis on A Multipotent Drug Chandraprabha Vati - Review Article; International Research Journal of Ayurveda & Yoga.2022; 5 (1),105-117.
13. Chander R, Khanna AK, Pratap P;Antioxidant activity of guggulsterone, the active principle of guggulipid from Commiphora mukul;Journal of Medicinal Aromatic Plant Sciences 2002;24-370
14. Shishodia S, Aggarwal BB. Guggulsterone inhibits NF-kappaB and Ikappa Balpha kinase activation, suppresses expression of anti-apoptotic gene products, and enhances apoptosis. J Biol Chem. 2004;279(45):47148-58.