website : www.ijacare.in e-ISSN No.: 2457-0443
INTERNATIONAL JOURNAL OF AYUSH CASE REPORTS (IJA-CARE)

A Constitutional Homeopathic Management of Chronic Stye: A Case Report

Likhitha A P,[1*] Anusuya M Akareddy[2]

[1] PG Scholar, MD (Part 2), [2] HOD, Dept. of Repertory, Government Homoeopathic Medical College and Hospital, Bangalore, Karnataka, India.

ABSTRACT:
A 25-year-old female working in medical coding presented with a complaint of swelling in the lower eyelid of the right eye for the past 1 year and 8 months. The complaint began as a small, painful, reddish eruption, which increased in size within 4–5 days, accompanied by burning, stinging pain and watering of the eyes. On local examination, a nodular swelling was observed. Routine blood tests were normal. No systemic illness was noted. Based on clinical features, a provisional diagnosis of external hordeolum (stye) was made. She was previously treated with topical antibiotic ointment, which temporarily reduced pain and redness but failed to eliminate the swelling completely. Surgical excision was advised, but the patient declined. A detailed homeopathic case-taking revealed key etiological factors and characteristic symptoms such as stress from overwork, competitive nature, communicative, irregular menses, and thermal intolerance to cold. The remedy Staphysagria 200C was prescribed based on the totality of symptoms. Over subsequent follow-ups, the swelling gradually reduced, and no recurrence was noted. This case highlights the scope of individualized homeopathic intervention in resolving chronic styes by addressing both local pathology and the underlying constitutional susceptibility.

KEYWORDS: External Hordeolum, Homeopathy, Staphysagria, Stye.

Received: 08.08.2025 Revised: 29.08.2025 Accepted: 08.09.2025 Published: 16.09.2025

Creative Commons Attribution-Non-Commercial-No Derivatives 4.0 International License
© 2025 International Journal of AYUSH Case Reports | Published by Tanaya Publication, Jamnagar.

QR Code
DOI 10.70805/ija-care.v9i3.772

***Corresponding Author:**
Dr. Likhitha A P
PG Scholar, MD (Part 2), Dept. of Repertory,
Government Homoeopathic Medical College and Hospital,
Bangalore, Karnataka, India.
Email: likhithaap09@gmail.com

INTRODUCTION:

A stye, medically termed a hordeolum, is an acute localized infection or inflammation of the eyelid, commonly involving the sebaceous (Zeis) or apocrine (Moll) glands. It typically presents as localized, painful, erythematous, pustular swelling. Styes, are a common condition across all age groups, primarily caused by Staphylococcus aureus. Adults may be more prone due to the increased viscosity of the sebum.[1]

While styes are usually self-limiting, in many cases, the lesion drains spontaneously and

resolves without treatment; however, the inflammation can spread to other ocular glands or tissues, and recurrences are common. [2] Chronic or recurrent episodes may indicate an underlying predisposition or lowered local immunity, often associated with predisposing factors such as eye strain due to muscle imbalance or refractive errors, habitual rubbing of the eyes, poor eyelid hygiene, use of contaminated cosmetics, contact lens use, excessive intake of carbohydrates and alcohol or systemic conditions like diabetes, and chronic blepharitis. [3]

The primary diagnostic tool for styes is a careful clinical examination.[4] It includes a history, physical inspection of the eyelid with a magnifying lamp (slit lamp) to assess the lump's size and location. Conventional management includes warm compresses, topical and systemic antibiotics, and, in persistent cases, surgical drainage. However, such approaches may offer only temporary relief, especially in chronic or recurrent cases, and do not address the root cause or prevent recurrence. In *Homeopathy*, with its holistic and individualized approach, remedies are selected based on a detailed understanding of the patient's constitution and characteristic symptoms.[6]

In this case, the remedy Staphysagria 200C was selected considering the patient's constitutional traits. The intervention was non-invasive, safe, and resulted in complete resolution and long-term relief without recurrence. This highlights the importance of individualized homeopathic management in chronic localized infections like a stye.

CASE REPORT:

Chief complaint:

A 25-year-old female, medical coder by profession from Bengaluru, belonging to a middle socio-economic family, who came to the OPD of Government Homoeopathic Medical College and Hospital, Bangalore, on 20/07/2024, presented with painful swelling in the lower eyelid of her right eye since 1 year and 8 months.

History of chief complaints: The swelling started as a painful, red eruption, increased to pea size in 4–5 days, associated with burning pain, watery eyes, and pustular discharge. Antibiotics offered relief in redness and pain but failed to resolve the lesion completely. Surgical removal was suggested.

Past medical history & Family history: Not significant.

Personal History:

Dietary habit: Mixed; appetite and thirst are good; desires for a variety of food and drinks. **Bowel and Urinary habit:** Bowel regular, bladder normal. **Sleep Habit:** Sound sleep. **Menstrual history:** irregular, profuse bleeding with clots, and dysmenorrhea.

Mental health: The patient is talkative. She described herself as hard working, industrious, and ambitious, often taking her responsibilities seriously and working late into the night.

General examination: The patient was moderately built and nourished with a BMI of 19.6 kg/m². The scalp was healthy. Ears and nose examined were normal. Oral cavity – NAD, uncoated tongue. There is no evidence of pallor, cyanosis, clubbing, edema, icterus, or generalized lymphadenopathy. Vital signs were within normal limits.

Local examination(Torch light): Firm, tender nodule persisting in the right lower eyelid.

Provisional diagnosis: External hordeolum(stye) of the right eye.

THERAPEUTIC INTERVENTION:

The remedy Staphysagria was selected after repertorizing the case using the Synthesis repertory in RADAR software.[7] The remedy scored highest based on mental and physical general symptoms, including characteristic features of the patient. The selection was further confirmed through materia medica references, aligning the patient's symptomatology with the remedy picture.[8,9]

A single dose was prescribed by the homeopathic principle of the minimum dose of the similimum. A moderate potency of Staphysagria 200C was chosen. On 20/07/2024, the first prescription was made with advice to avoid touching the lesion by hand, refrain from using any external applications, maintain adequate hydration, and ensure proper sleep. The patient was monitored through regular follow-ups to assess progress.

Table-1: Case processing

	Analysis	**Evaluation**	**Miasm**
1. Mental general			
Competitive	Uncommon	3	Sycotic
Communicative	Uncommon	3	Psora
Mental exertion	Uncommon	2	Sycotic
Creative activity desires	Uncommon	2	Sycotic
2. Physical general			
Irregular menses	Uncommon	3	Psora
Chilly patient	Uncommon	2	Psora
Desires a variety of food & drink	Uncommon	3	Psora
3. Characteristic particulars			
Chronic stye <mental exertion	Uncommon	3	Sycotic

Table- 2: Time line & follow up.

Date	**Symptoms**	**Prescription**
30-08-2024	No change in the lesion Appetite- good Sleep- sound	PL BD for 1month
16-10-2024	Size of the lesion has reduced Menses- moderate flow without clots	PL BD for 1month
20-12-2024	Stye resolved General condition is good No any fresh complaint	PL BD for 1month

Figure 1: Before treatment - External view of the right eye.

Figure 2: Before treatment – Palpebral conjunctiva of the right lower eyelid.

Figure-3: After treatment - External view of the right eye.

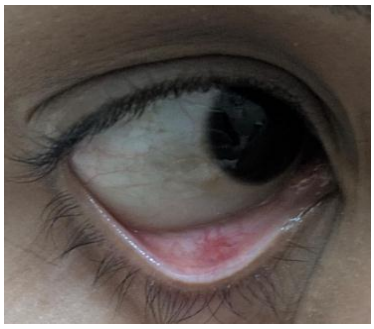

Figure-4: After treatment – Palpebral conjunctiva of the right lower eyelid.

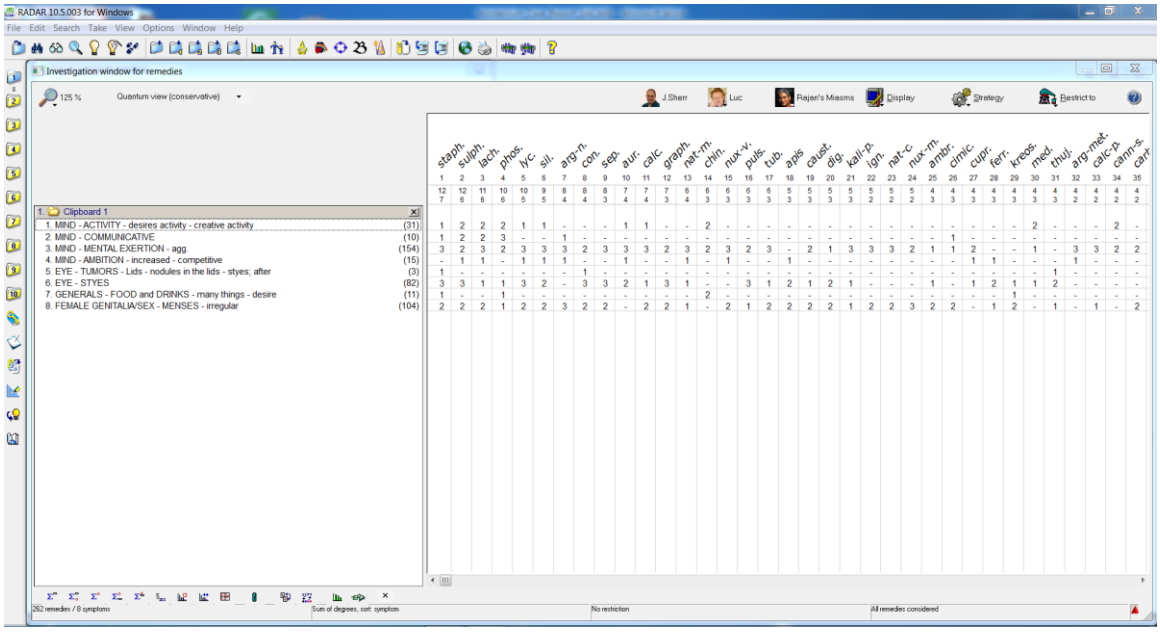

Figure- 5: Repertorization sheet from RADAR

DISCUSSION:

The case indicates that constitutional remedy selection based on individual symptomatology led to improvement without surgical intervention. The remedy matched the patient's constitutional state and provided gradual but consistent improvement in both local symptoms and general well-being. Staphysagria acts on the glandular structures, producing chronic glandular swellings. It is particularly indicated in cases where suppressed emotions and prolonged mental exerton predisposes to recurrent infections. This constitutional affinity explains its beneficial action in recurrent styes, where it not only reduces local inflammation but also corrects the underlying susceptibility that maintains the chronic condition. [5] Staphysagria matched the patient's constitutional state, reinforcing the remedy choice. Such cases support individualized homeopathic treatment even in surgical conditions like chronic hordeolum.

CONCLUSION:

Constitutional *homeopathy* can effectively manage chronic hordeolum without surgical intervention. Proper repertorial analysis and remedy selection are crucial for long-term resolution.

Limitation of study:

As a single case report, this study has inherent limitations. The outcomes observed may not be generalizable to a broader population without further evidence from case series or controlled studies. Patient follow-up was limited to a few months; hence, long-term recurrence prevention cannot be fully assured. Despite these limitations, the case offers valuable clinical insights into individualized homeopathic management of chronic hordeolum.

Acknowledgement:
The author sincerely thanks the patient for her cooperation and for consenting to the use of her clinical details and photographs for academic publication. Gratitude is also extended to GHMC (Government Homeopathic Medical College) for providing the clinical platform and necessary support during case documentation and follow-up.

Conflict of interest: The author declares that there is no conflict of interest.

Guarantor*:* The corresponding author is the guarantor of this article and its contents.

Source of support: None

How to cite this article:
Likhitha A P, Anusuya M Akareddy. A Constitutional Homeopathic Management of Chronic Stye: A Case Report. Int. J. AYUSH CaRe. 2025;9(3): 634-639. DOI 10.70805/ija-care.v9i3.772

REFERENCES:

1. Willmann D, Guier CP, Patel BC, Melanson SW. Hordeolum (Stye). StatPearls [Internet]. Treasure Island (FL): StatPearls Publishing;2024 [Last Accessed on 29th August 2025]. Available from: https://www.ncbi.nlm.nih.gov/books/NBK459349/
2. Lindsley K, Nichols JJ, Dickersin K. Non-surgical interventions for acute internal hordeolum. Cochrane Database Syst Rev 2017;1(1):CD007742.
3. Khurana AK, Comprehensive Ophthalmology. Hordeolum. New Age

International (P) Ltd Publishers. New Delhi, 4th edition, 2007, p 345–346.
4. Doan S, Zagórski Z, Palmares J, Yağmur M, Kaercher T, Benítez-Del-Castillo JM, et al. Eyelid disorders in ophthalmology practice: results from a large international epidemiological study in eleven countries. Ophthalmol Ther. 2020;9(3):p 597–608.
5. Burt WH. Physiological Materia Medica. Staphysagria. B. Jain Publishers, New Delhi. 3rd edition, Reprint 2009, p 598-600
6. Hahnemann S, Organon of Medicine, B. Jain Publishers, New Delhi, 6th edition, 2002.
7. Rapid Aid to Drug Aimed Research (RADAR), version 10.5.003 [software]. Archibel; 2007.
8. Kent JT, Lectures on Homoeopathic Materia Medica, B. Jain Publishers, New Delhi. 2004, p 859–65.
9. Boericke W, Pocket Manual of Homoeopathic Materia Medica with Repertory, B. Jain Publishers, New Delhi, Reprint edition. p 607–608.